

# 15 ROOTT YEARS



## Casebook

15 Years of Clinical Confidence



# Placed with Precision. Proven in Practice.

## A Clinical Casebook — ROOTT Implant System

Every implant placement carries a decision. A judgment call. The kind that only comes from experience — and the right system behind you.

ROOTT was built by physicist and clinical experts who understood that gap. Not engineers working from a distance, but practitioners who have stood where you stand—weighing bone quality, patient anxiety, and a margin for error that simply does not exist in our field.

The result is a Swiss-engineered implant system that does not ask you to work around it. It works with you.

Seven implant types. One coherent system.

ROOTT R for dependable rootform stability.

ROOTT M for multi-unit cases, wide or narrow.

ROOTT C and CS for immediate loading in compromised bone.

ROOTT B and BS for the atrophied ridge where crestal bone is gone.

ROOTT P for the pterygoid region — no sinus lift required.





























Each implant has a specific job. Together, they cover every case that walks through your door — from a straightforward single restoration to a full-arch rehabilitation where other systems stop.

This casebook is not a brochure. It is a record of real decisions, documented by clinicians for clinicians. The cases here range from the routine to the complex, because that is what a Monday morning actually looks like.

Simple where it can be. Precise where it must be.



## Clinical Case Index

No.	Doctor		Case Title / Focus	Page
 1	Dr. Adam Nowicki		Full-Arch Immediate Implant Rehabilitation	4
 2	Dr. Konstantinos Manolarakis		Full-Arch Maxillary Rehabilitation – All-on-4	8
 3	Dr. Bruno Viana Reis		Immediate Implant Placement – Tooth 46	13
 4	Dr. Tome Piperevaliev		Immediate Implant Placement – Tooth 12 Aesthetic Zone	16
 5	Dr. Vladislavs Ananĵevs		Zero Bone Loss & Conometric Crown – Tooth 26	19
 6	Dr. Roman Novichenko		Full-Arch Rehabilitation – All-on-6	22
  7	Dr. Mohamed Babouche		Graftless Maxillary Rehabilitation with ROOTT M & P	29
  8	Dr. Henri Diederich		BTB Full-Arch Rehabilitation with ROOTT M & P	35
  9	Dr. Mohamed Babouche		3-Week Protocol with ROOTT M & P	38
 10	Dr. Fernando Mora Estévez		Immediate Loading with ROOTT C One-Piece Implants	42
 11	Dr. Adam Nowicki		Graftless Narrow Ridge Rehabilitation with ROOTT C	45
  12	Dr. Sergio Zajdenberg		Full-Arch Monoblock Rehabilitation with ROOTT C & BS	52

## ROOTT R

### Clinical situation

Terminal Dentition Patients with advanced periodontal disease, widespread dental caries, missing teeth and failing restorative work (broken bridges/crowns).

Gender: Male

Age: 60

Clinical Scenarios Immediate Implants (Same Day):

Teeth are extracted, ROOTT R implants are placed

Lower All on 4

Upper All on 6

Removable provisional prosthesis on

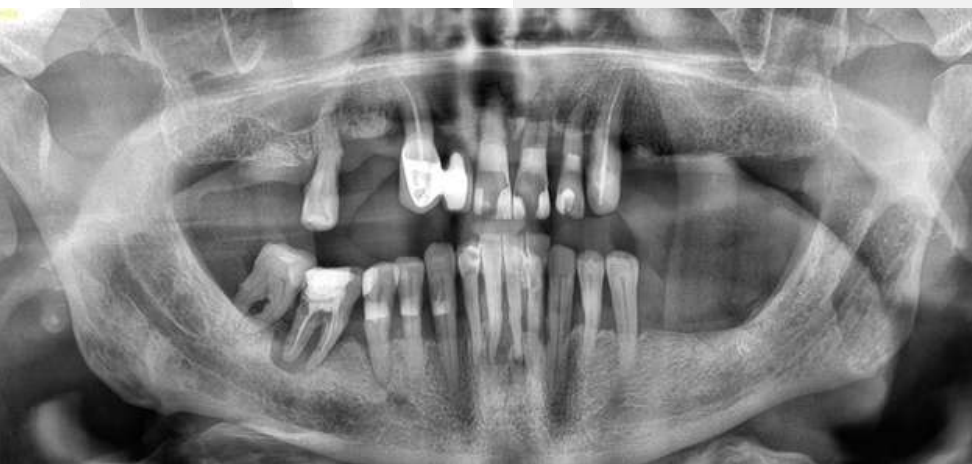Transitional Ball and socket implants is loaded within hours 24-72hours.

Delayed Loading Protocol : Implants are placed, covered for 3 months for osseointegration, and a final prosthesis is delivered later.

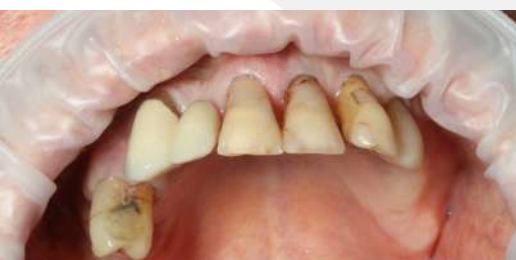

### Dr. Adam Nowicki DMD, PhD

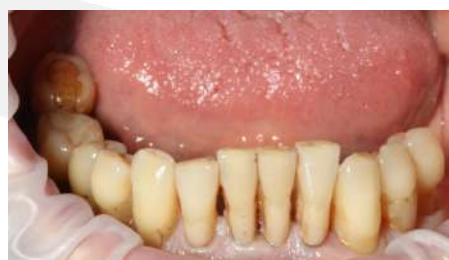- A premier Polish expert in Digital Implantology and Prosthetic Reconstruction, based in Lubin and Wrocław.
  - Developer of the Croco Eye Technique (CET)—a surgical method for the simultaneous removal of sinus cysts and sinus floor elevation.
  - Assistant Professor at the Pomeranian Medical University (Szczecin), specializing in the biomechanics of the masticatory system.
  - Known for bridging Clinical Dentistry with Mechanical Engineering, specifically in the 3D printing of dental resins and intraoral welding.
- An international lecturer (ITI, Straumann) recognized for his expertise in Full-Arch Immediate Restorations using digital workflows.



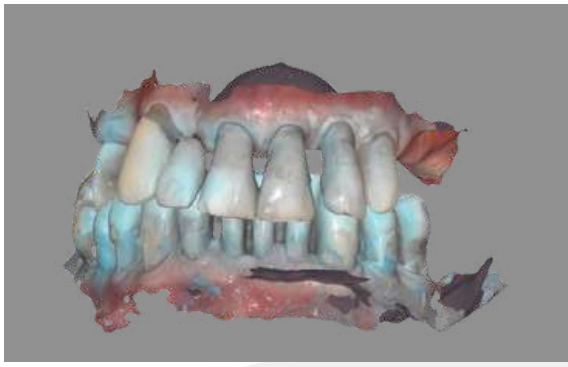Preoperative panoramic Xray




Preoperative Patient Photograph  
upper



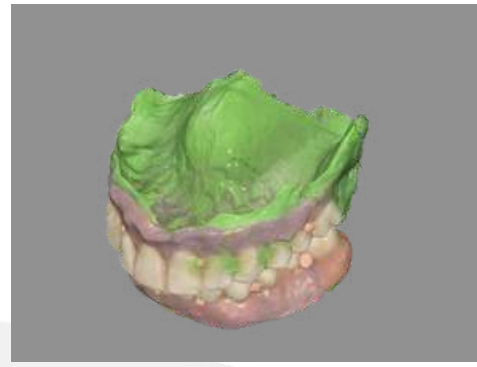
Preoperative Patient Photograph  
lower



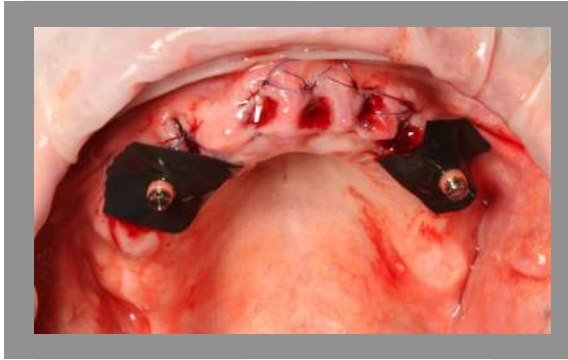
Bite Scan of the patient



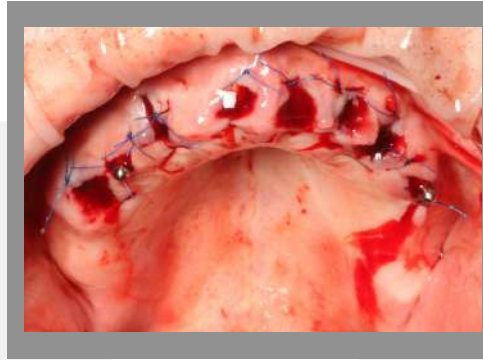
Case Planning With occlusion



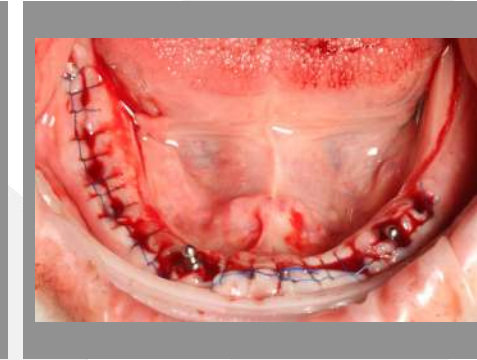
New Bite Scan in Place



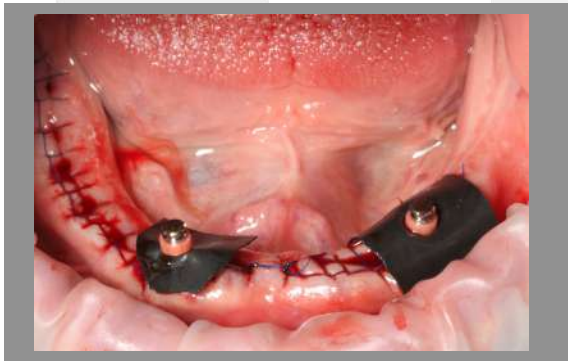Maxilla Locator Attachment for overdenture pick-up



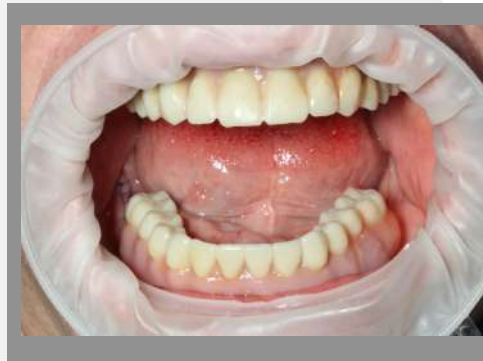Maxilla Surgery with Implant Placemnt & Transitional Implants for Provisonal overdentures



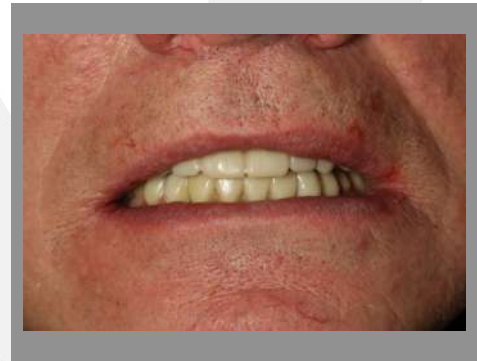Mandible Surgery with Implant Placemnt & Transitional Implants for Provisonal overdentures



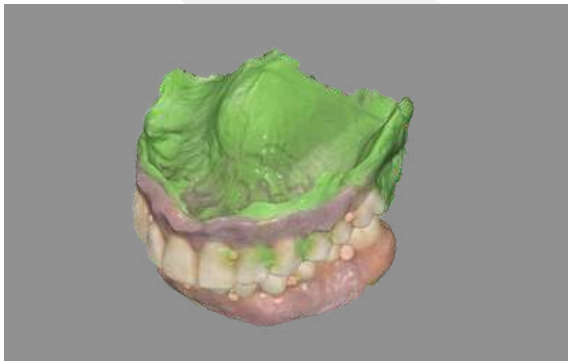
Mandible Locator Attachment for overdenture pick-up




Overdentures in place



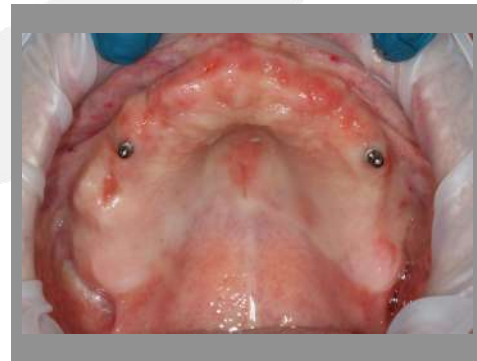Overdentures in occlusion



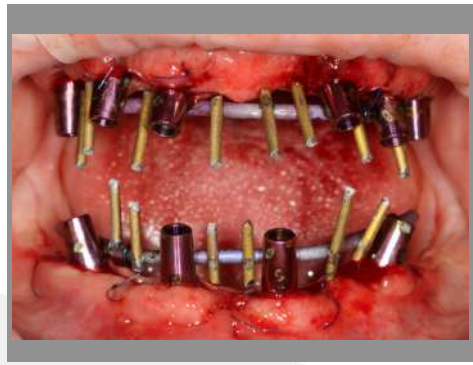
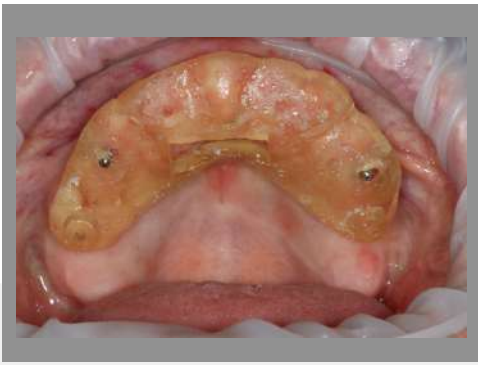
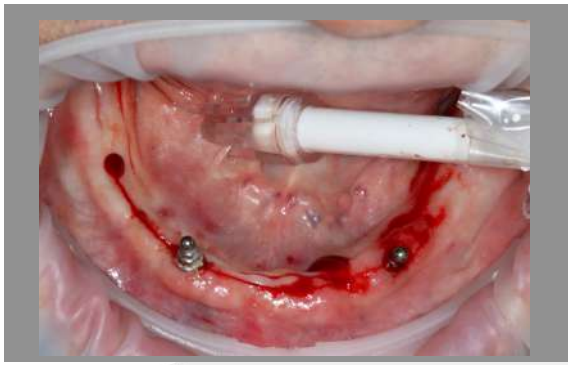
Bite Occusal scan of the overdentures with occlusion



Merge of Occlusion with the Denture scan from previous



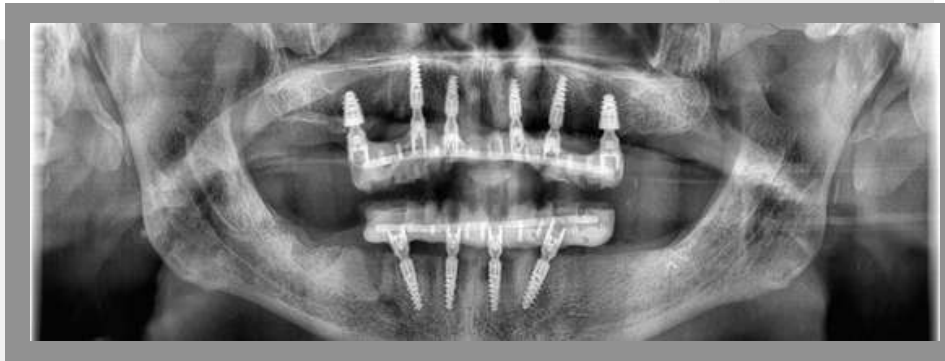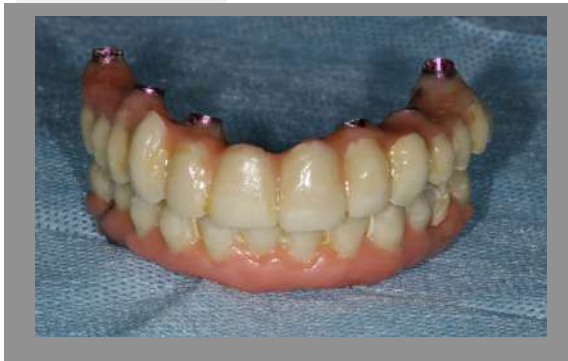Upper Healed with Transitional implants



Lower Healed with Transitional implants and uncovering of healed implants

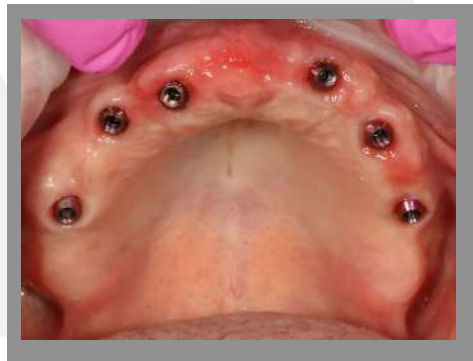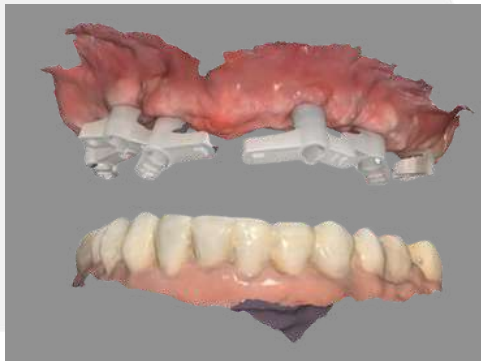
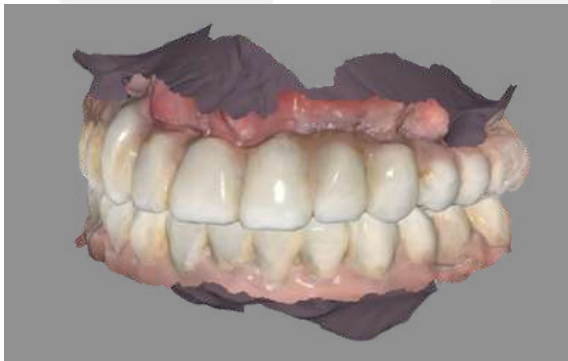Upper Healed with Transitional implants with Guide in place to located healed implant location

Upper & lower implants with temporary abutment with intraoral welding



Upper & lower Temporaries in place

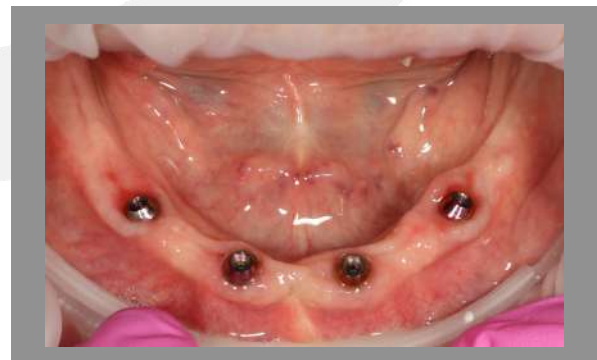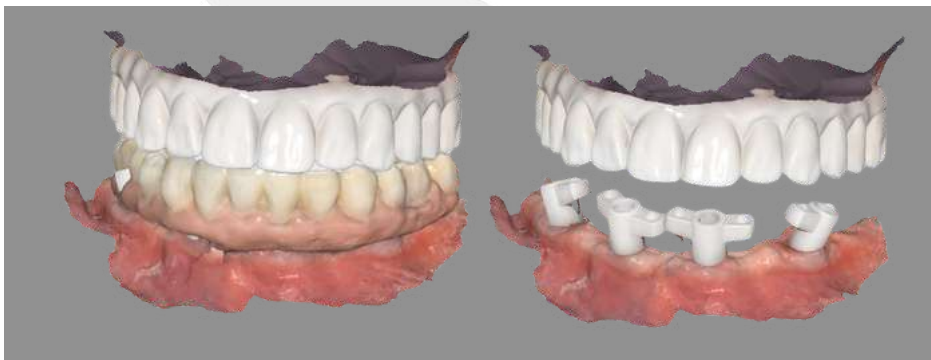Panoramic Xray with Provisional sin place



Bite Scan of temporaries in occlusion

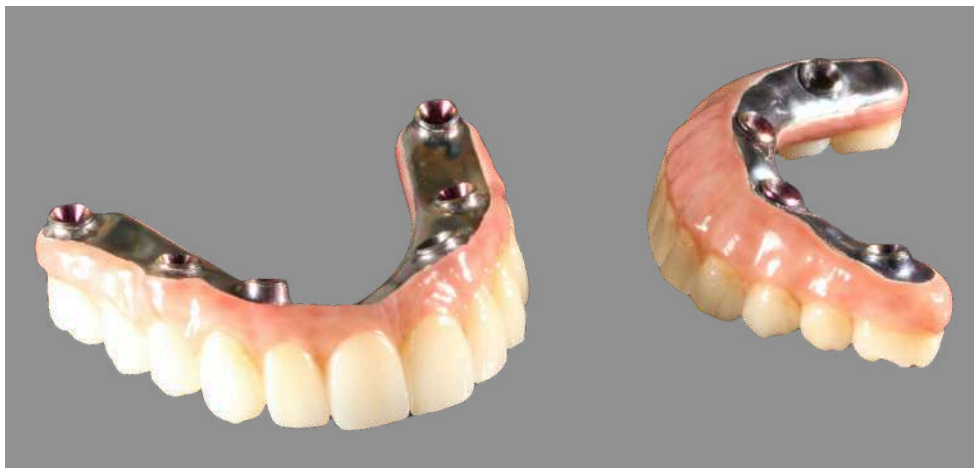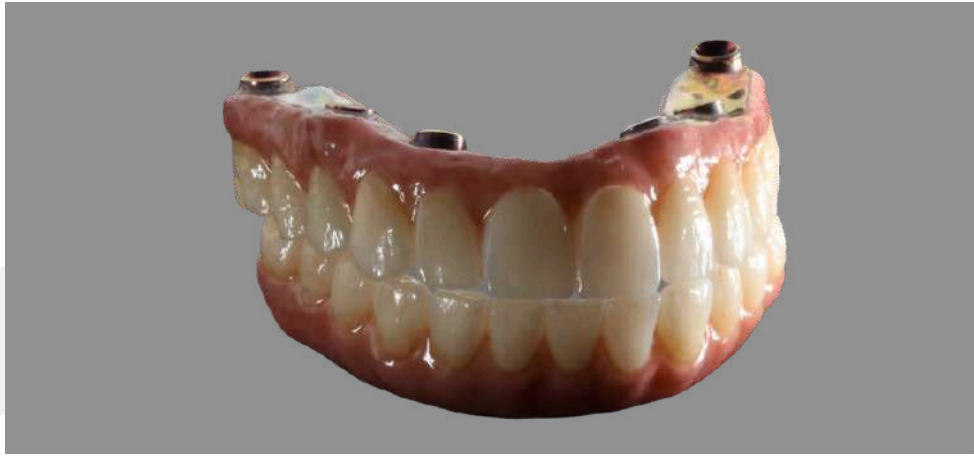Full arch scan with Scan flags

Healed implants after removing temporaries in maxilla

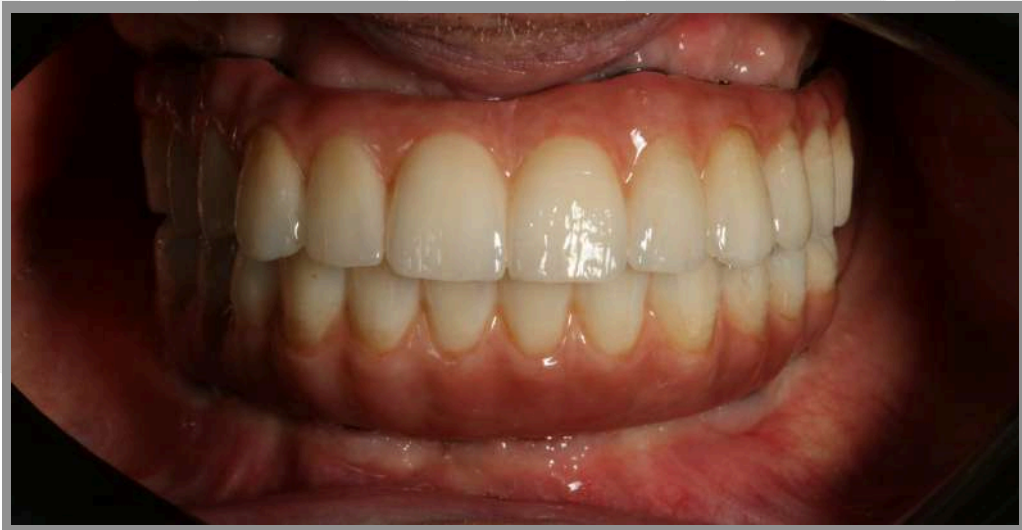

Bite scan with permanent deisgn

Healed implants after removing temporaries in mandible



Permanent prosthesis Metal fused to porcelain



Permanent prosthesis Metal fused to porcelain in patients mouth



## Clinical cases

# ROOTT R

### Clinical situation

The patient presents with failing maxillary dentition (upper jaw) that can no longer be restored or saved, requiring full-arch extraction and comprehensive rehabilitation.

Gender: Female

Age: 45

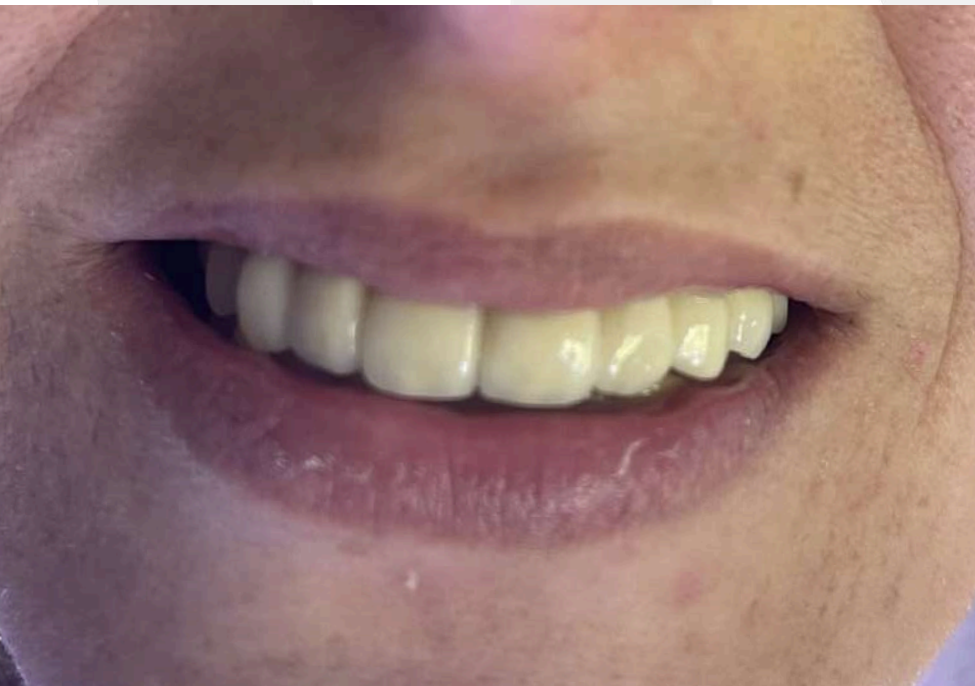A full-arch rehabilitation using the All-on-4 treatment concept. Following the extraction of the failing maxillary teeth, four ROOTT R implants are strategically placed—two vertically in the anterior region and two in the posterior region—to maximize the anteroposterior (A-P) spread and avoid critical anatomical structures. The treatment follows a hybrid workflow with a delayed loading protocol. Instead of placing a fixed temporary bridge on the day of surgery, the implants are allowed to heal and osseointegrate undisturbed for 3 months before the final fixed prosthesis is attached.



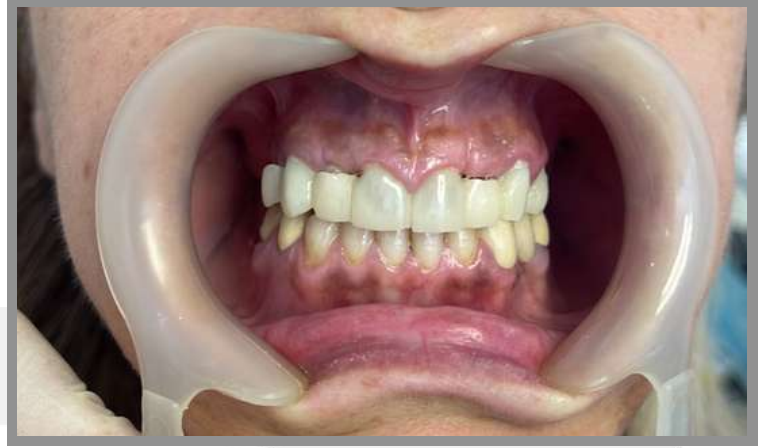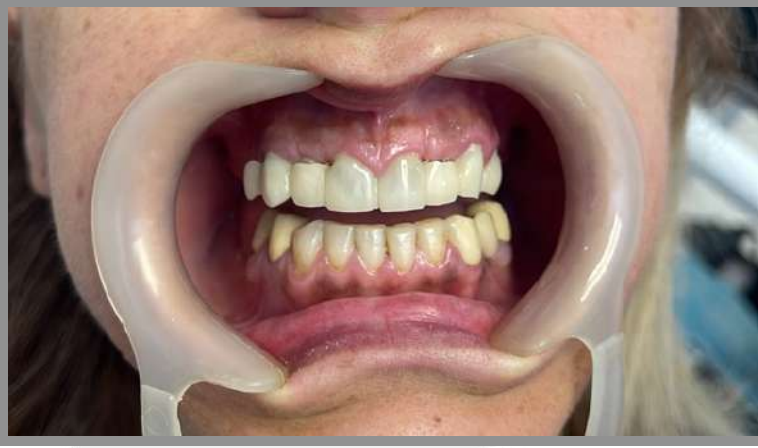## Dr. Kostas Manolarakis

### DDS

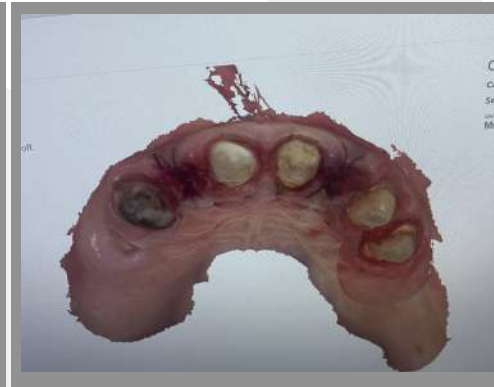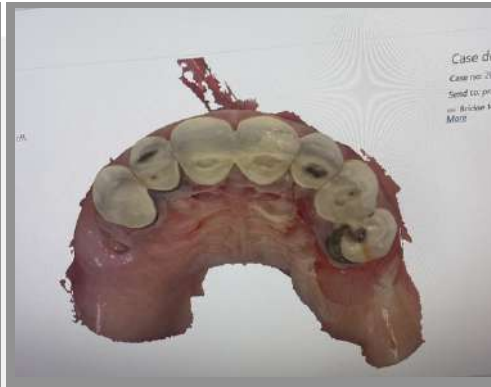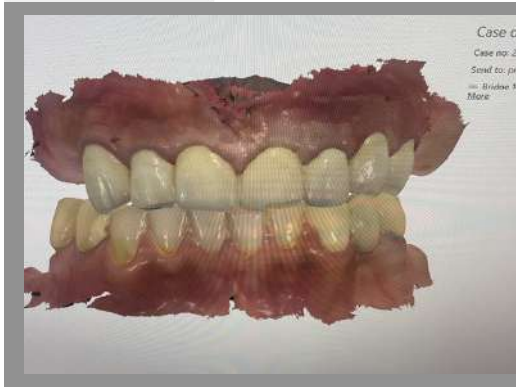- Served in multiple General Hospitals in Greece as a dentist (2000)
- Running a private dental clinic in Heraklion since 2000
- Advanced training in Oral Diagnostics & Radiology – University of Athens (2008)
- Certified in CA® CLEAR-ALIGNER Invisible Orthodontics
- Specialized in surgical & prosthetic implantology for 15+ years
- Extensive experience through international seminars and clinical practice
- Among the first dentists in Crete to apply immediate loading implant procedures



Happy patient



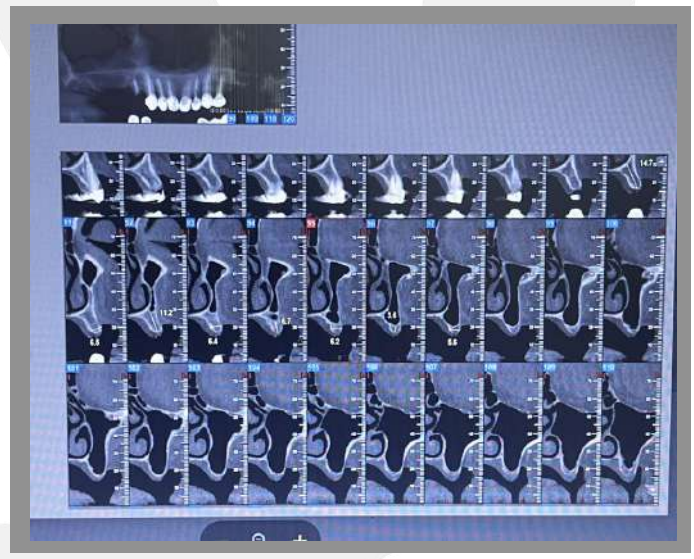

Clinical profile patient front



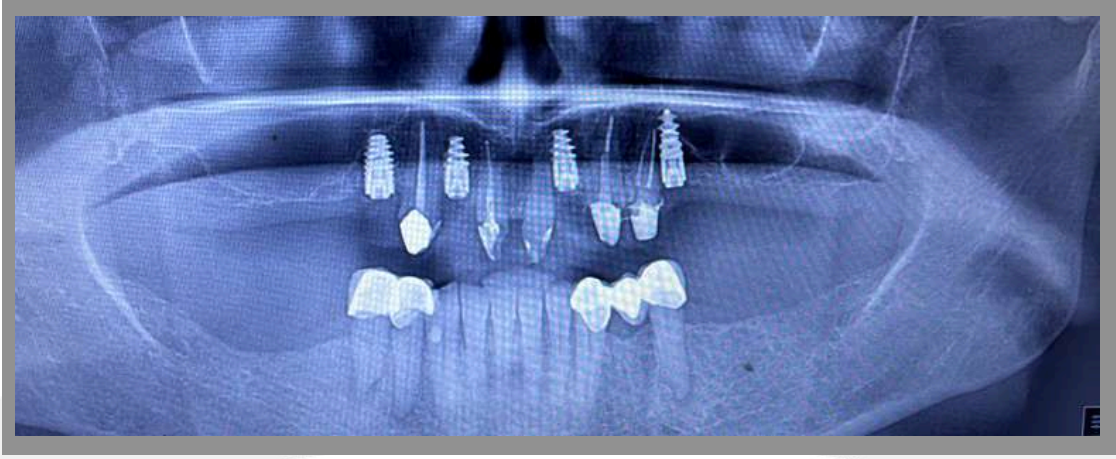
upper preoperative Intraoral Scan with temporary teeth & bite

upper preoperative Intraoral Scan with temporary teeth occlusal view

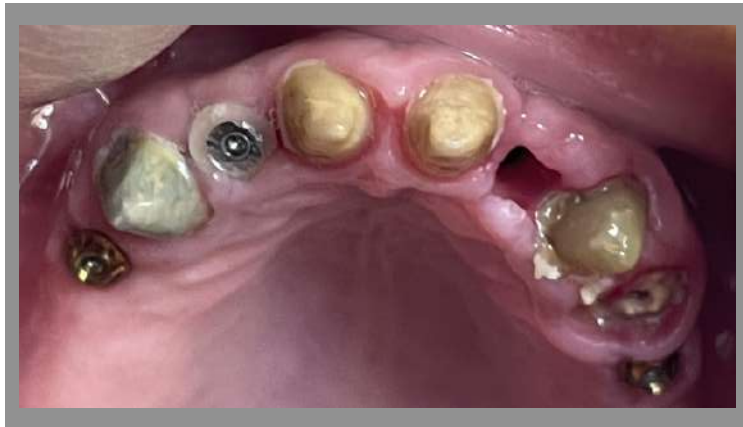upper post operative Intraoral Scan with implant placed



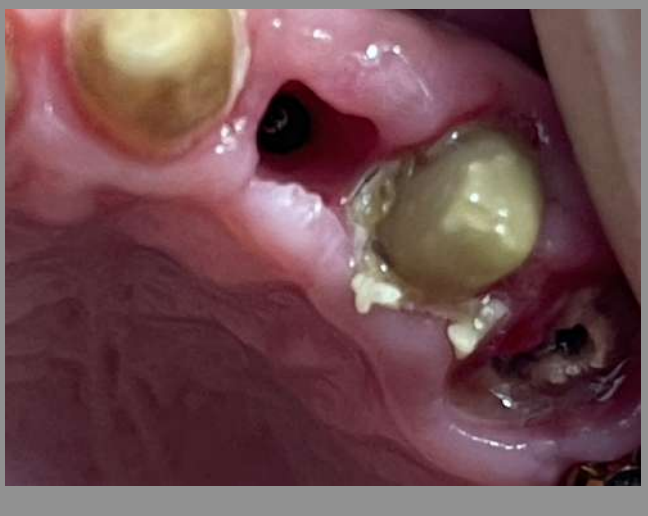Preoperative CBCT



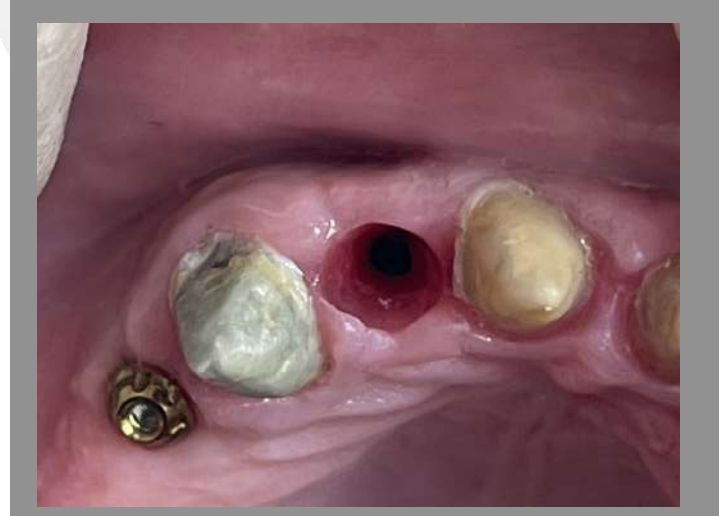Post operative Panoramic Xray Implant placed



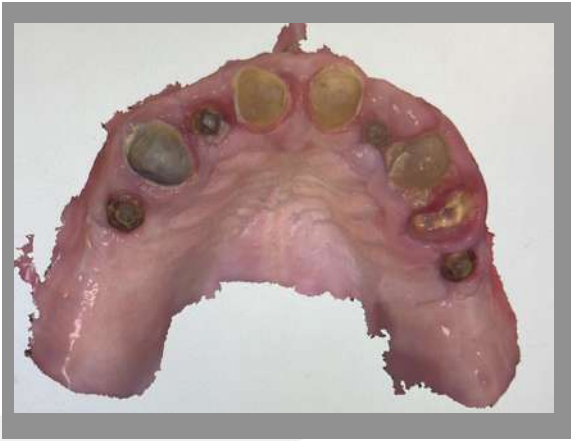
Post operative post healing Occusal view of implants placed at 12/22 site 14/25 with removed healing at site 22



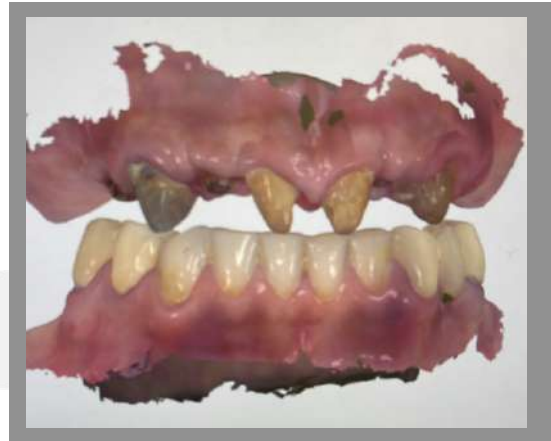Post operative post healing Occusal view healing at site 22



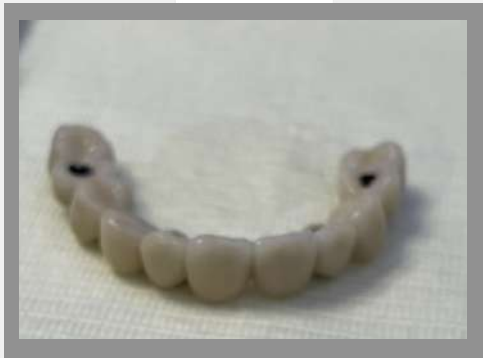Post operative post healing Occusal view healing at site 12



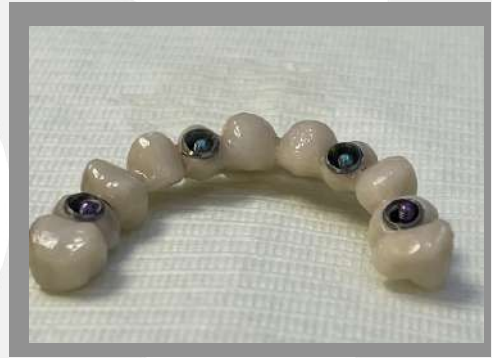Post operative post healing Occusal view  
healing at site



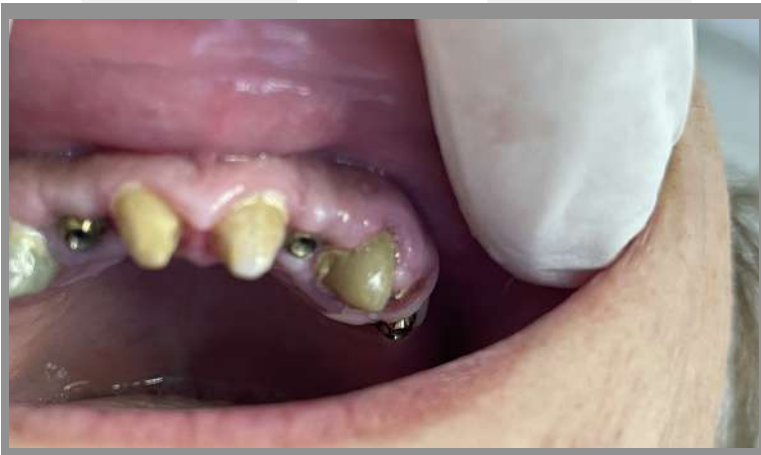Intraoral Scan



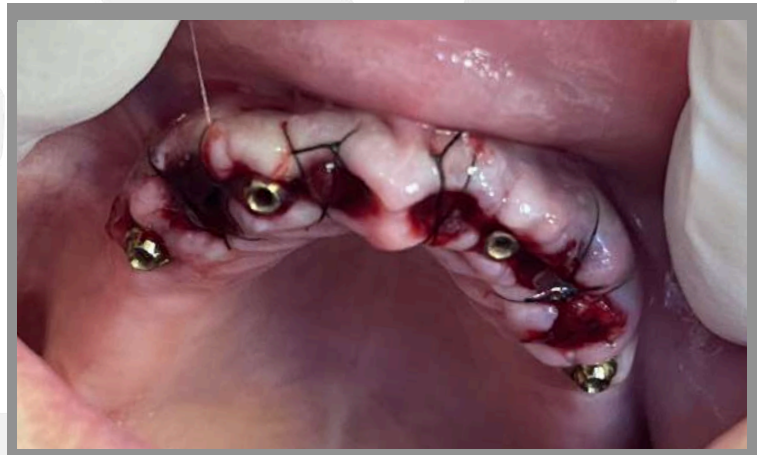
Final FP1 FULL Arch Zircoia prosthesis



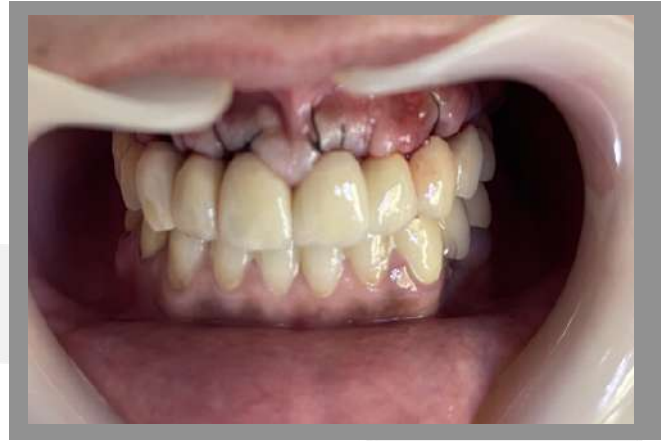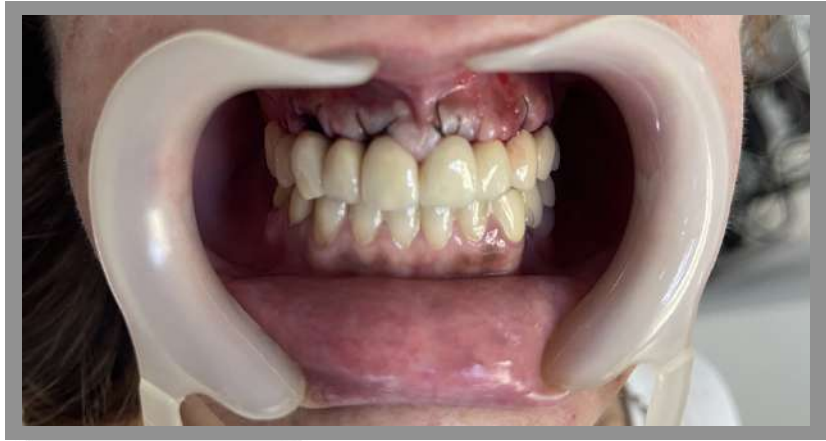Final FP1 FULL Arch Zircoia prosthesis with PCOM TI-  
base abutments



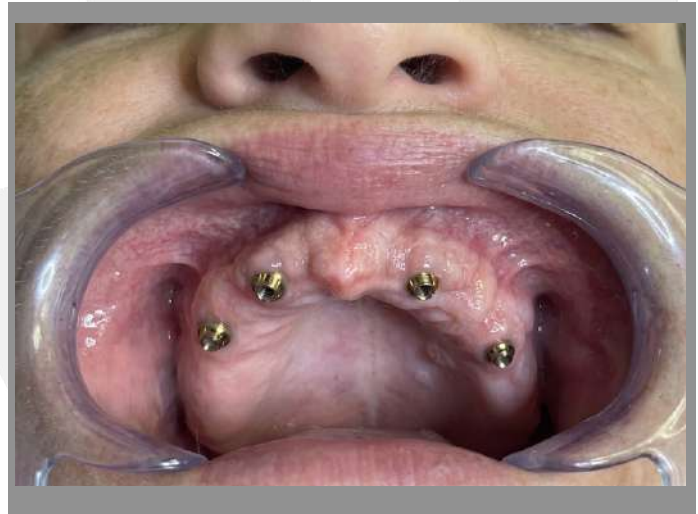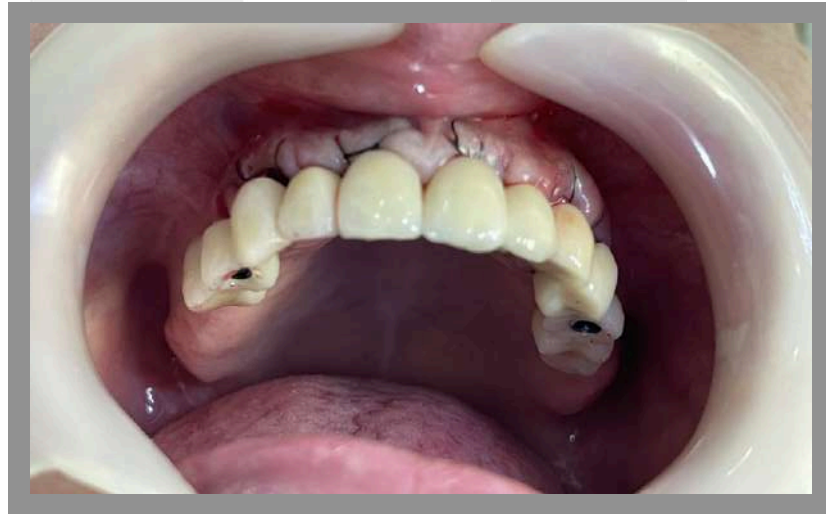Preextraction view



Post extraction view with sutures in place with collagen  
dressing

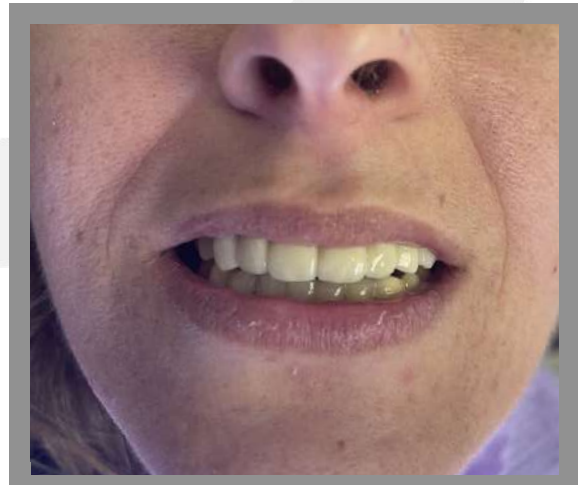
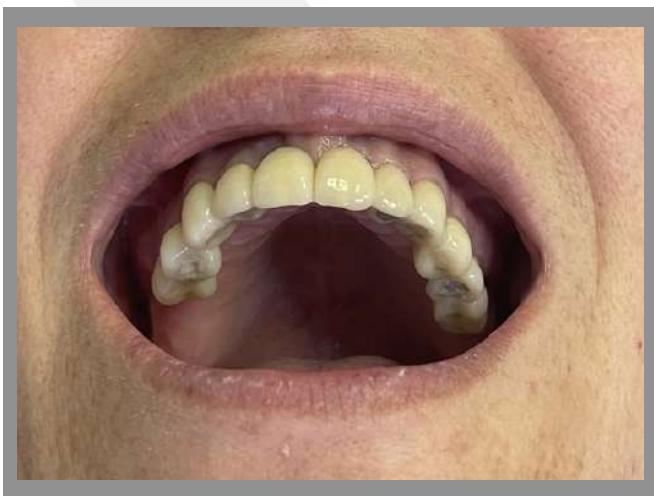

Immdetaie FP1  
Prosthesis Fixation post extraction



Immdetaie FP1  
Prosthesis Fixation post extraction intraoral view

Two months post healing after prosthesis removal



Follow-up after two months and maintenance

Follow-up patient view



# Clinical cases

## ROOTT R

### Clinical situation

The patient presented with a non-restorable tooth (46) in the posterior mandible, requiring extraction due to structural compromise. The clinical objective was to preserve alveolar bone architecture, minimize treatment time, and achieve predictable functional rehabilitation through immediate implant placement.

Gender: Female

Age:

Atraumatic extraction enabled immediate placement of a ROOTT implant (4.2 × 12 mm) with strong primary stability, positioned ~1.5 mm subcrestally for optimal emergence profile.

The residual gap was grafted using Qualybone BCP to preserve bone volume.

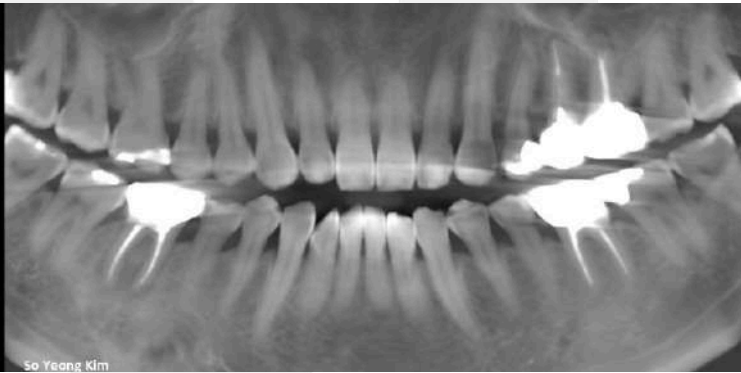A customized ZBL abutment was fabricated chairside for immediate soft tissue shaping.

Procedure was completed without complications, demonstrating a predictable and efficient posterior implant protocol.

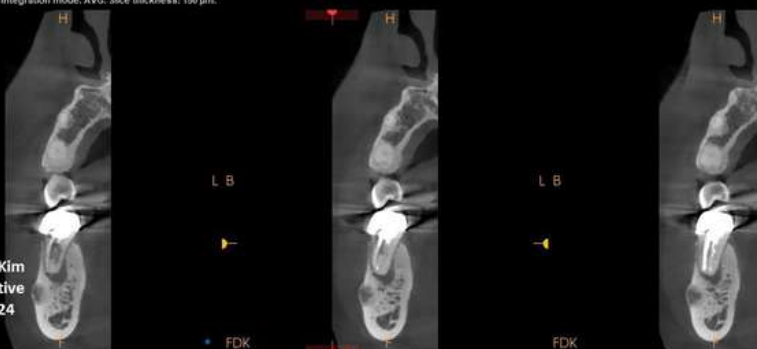

## Dr. Bruno Viana Reis DMD, MSc

- Implantologist & Oral Rehabilitation Specialist based in Ireland
- 20+ years of clinical experience in advanced dentistry and implantology
- Specialist in full-arch rehabilitation (All-on-4 / All-on-6) and complex implant cases
- Advanced expertise in guided surgery and fully digital workflows
- Key Opinion Leader (KOL) at ROOTT Implant System
- Co-Founder & Lead Dentist at a multidisciplinary clinic in Dublin
- Strong background in orofacial pain, TMD, and prosthetic rehabilitation
- Active lecturer with experience in academic teaching, research, and international congress presentations
- Master's Degree in Dental Medicine (Portugal) with residency in Implantology



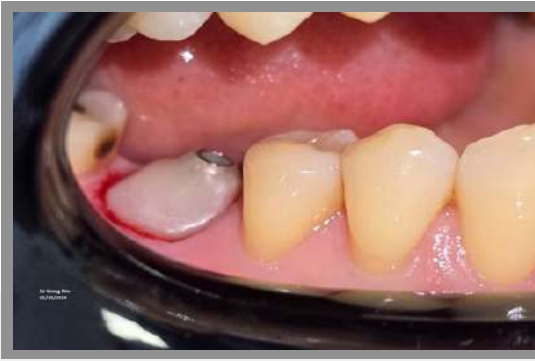PREOPERATIVE PANORAMIC XRAY 46 HOPELESS PROGNOSIS NON RESTORABLE MOLAR



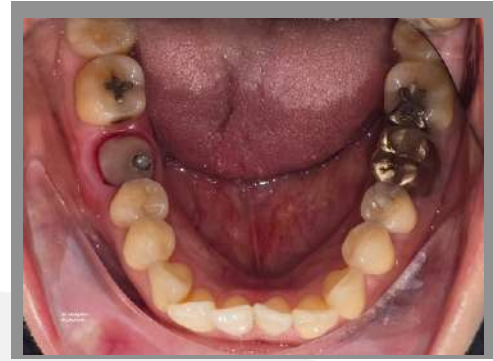INTRAOPRATIVE PIC BITE PROFILE LEFT PROFILE



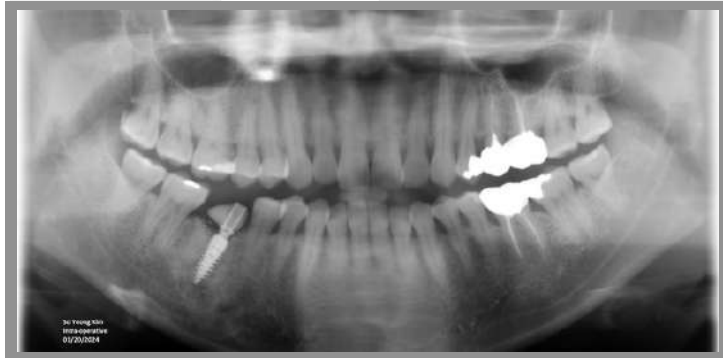
ZBL abutment with ZBL AHS solution for immediate molar modified



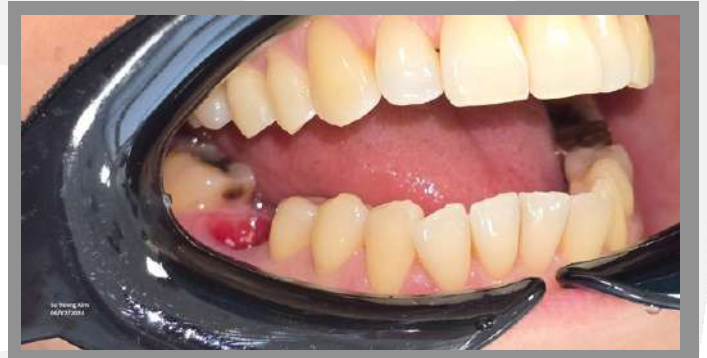ZBL abutment with ZBL AHS solution for immediate molar intraoral view



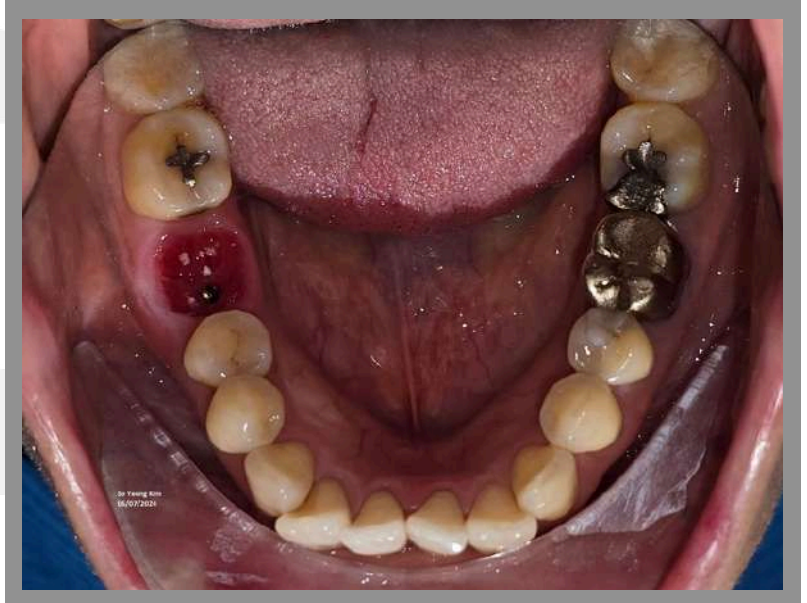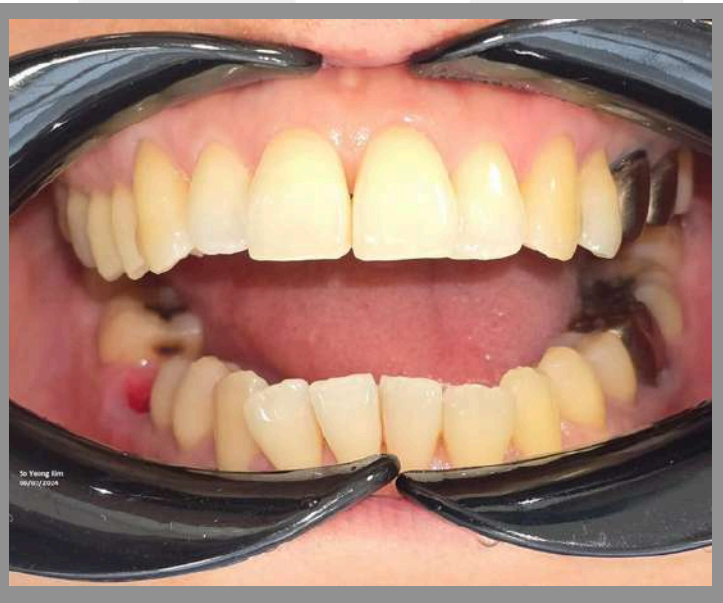POST -OPRATIVE intraoral view  
POST PLACEMENT ZBL AHS Socket  
sealing technique



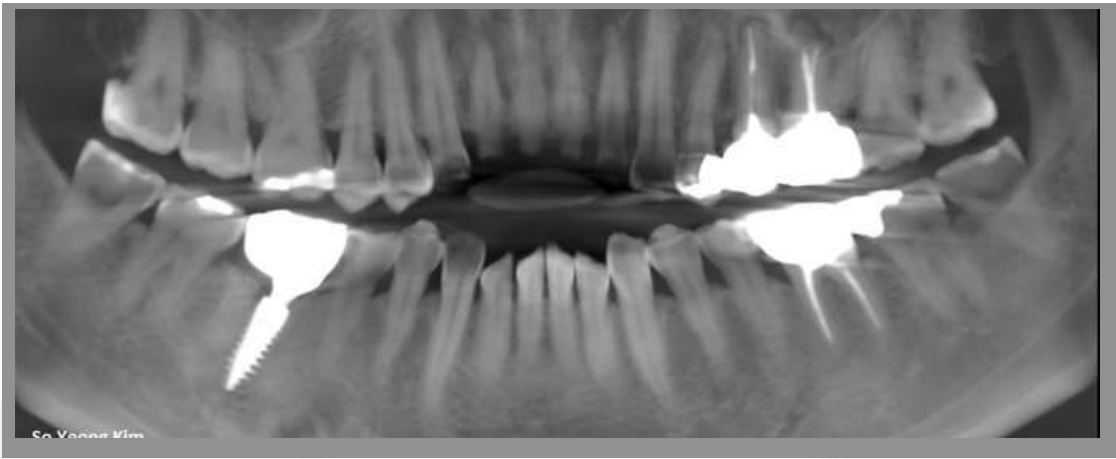
POST -OPRATIVE CBCT SECTION POST  
PLACEMENT ZBL AHS SST



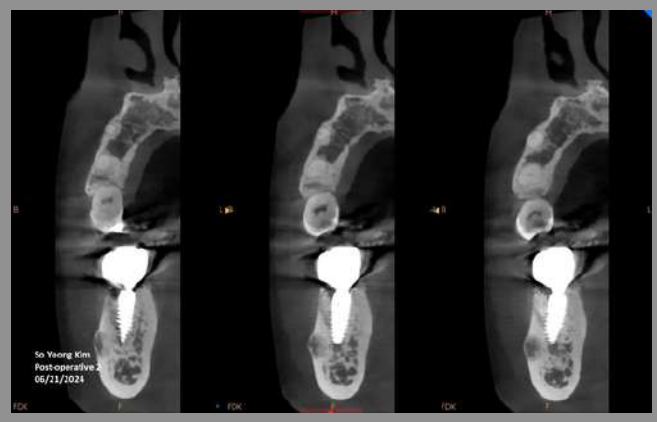POST - OPRATIVE intraoral lateral  
view healing after 3 months



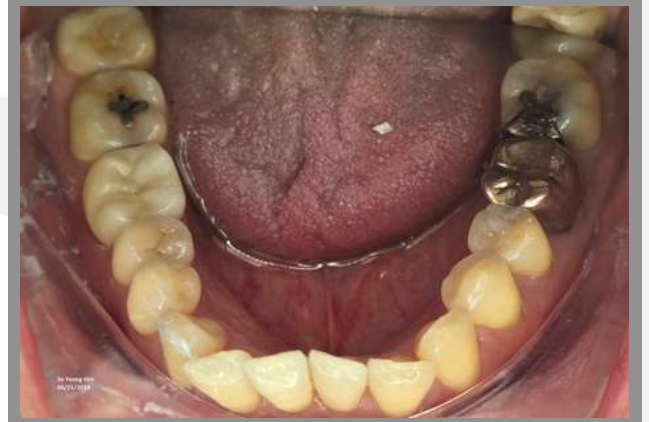
POST - OPRATIVE intraoral occlusal view healing after 3 months



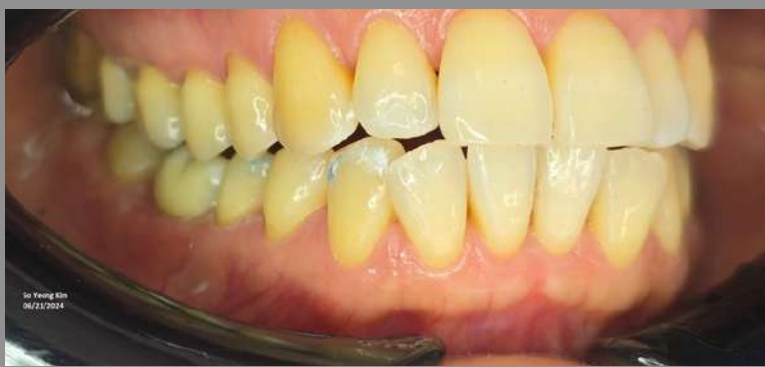PREOPERATIVE CBCT SECTION 46 PANORAMIC IMPLANT PLACEMENT



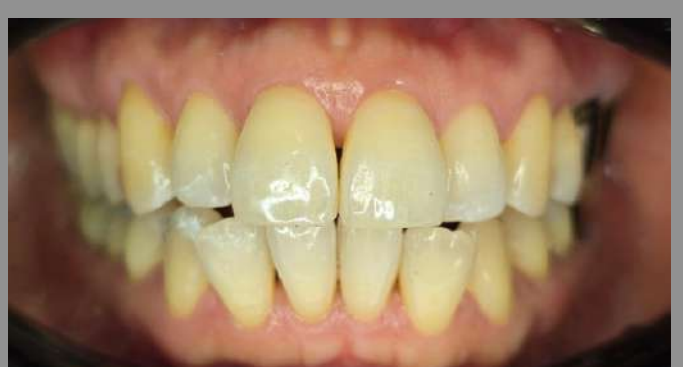PREOPERATIVE CBCT SECTION 46 BUCCO-PALATAL VIEW




Final Prosthesis in place occlusal view and natural soft tissue contours



INTRAORAL PIC BITE PROFILE RIGHT PROFILE



INTRAORAL PIC BITE PROFILE PROFILE



IOPA



## Clinical cases

# ROOTT **R**

### Clinical situation

A 45-year-old female patient presented with a non-restorable upper right lateral incisor (tooth 12) in the aesthetic zone, requiring a solution that preserves both function and gingival architecture.


Gender: Female

Age: 45

Atraumatic extraction was performed to preserve the buccal bone. A ROOTT R3514 implant (3.5 × 14 mm) was immediately placed in a prosthetically driven position, engaging apical and palatal bone to achieve high primary stability and optimal emergence profile.

The residual gap was managed with grafting where required to maintain buccal bone thickness.

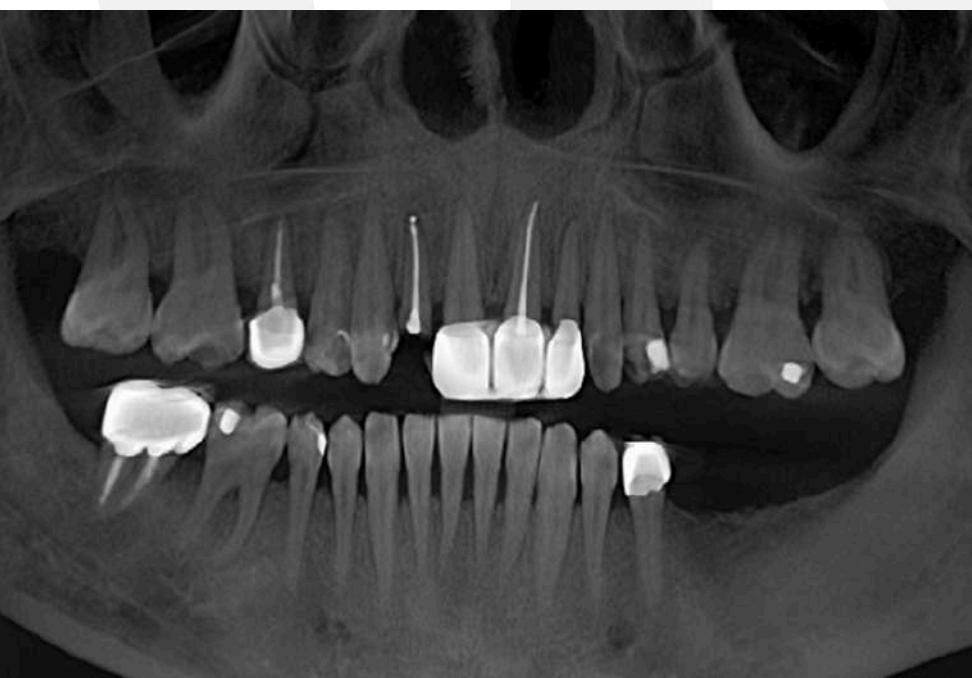
A customized provisional solution was used to support soft tissue shaping, followed by final digital workflow and placement of a definitive ceramic crown after osseointegration.



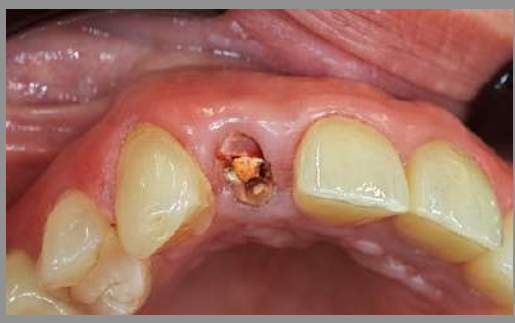## Dr. Tome Piperevaliev

DMD, PhD

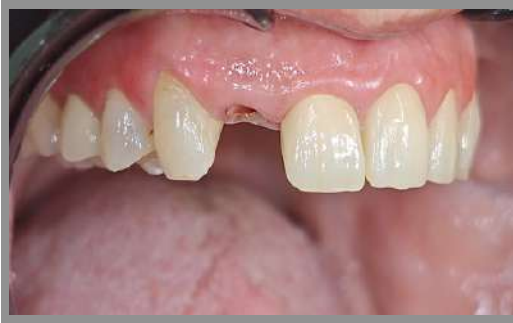- Oral Surgeon & Implantologist based in North Macedonia
- Resident in Oral Surgery and Implantology with advanced clinical focus
- Specialist in Immediate Loading protocols and Compressive Implant Systems
- Extensive experience in full-arch rehabilitation and implant-supported prosthetics
- International speaker delivering lectures on modern implantology techniques
- Focused on bar-retained restorations and immediate loading workflows
- Trained across Europe in microsurgery, sinus lift procedures, and advanced surgical techniques
- Active participant in leading international congresses including AEEDC Dubai



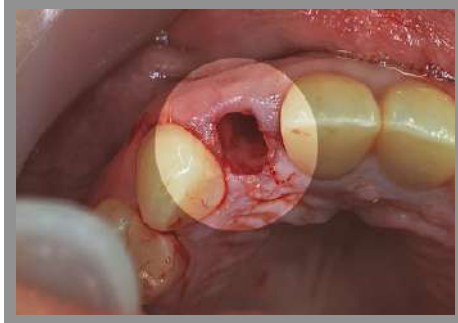
Pre-operative Panoramic Xray with hopeless lateral incisor 12



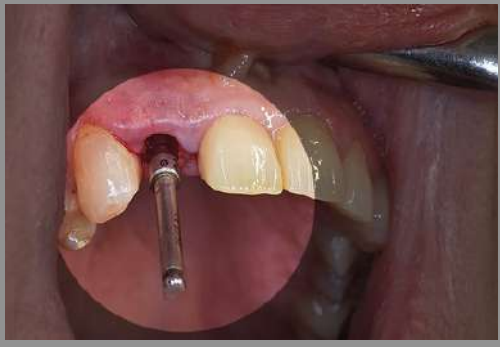
Unrestorable Lateral incisor 12



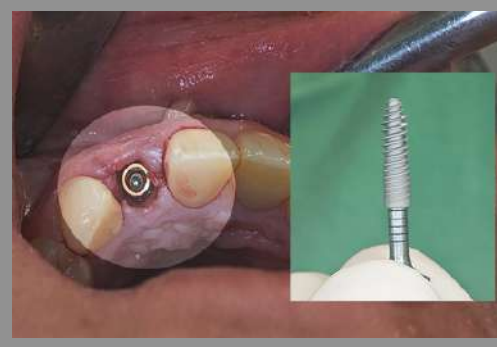
Immediate post extraction view



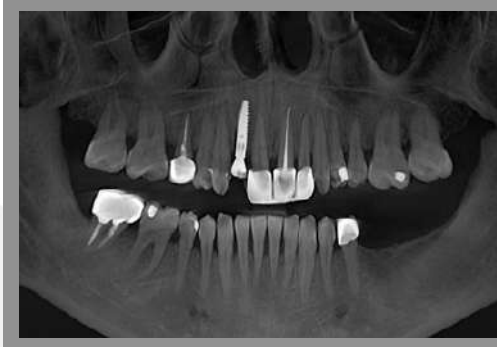Immediate post extraction after socket debridement and cleaning



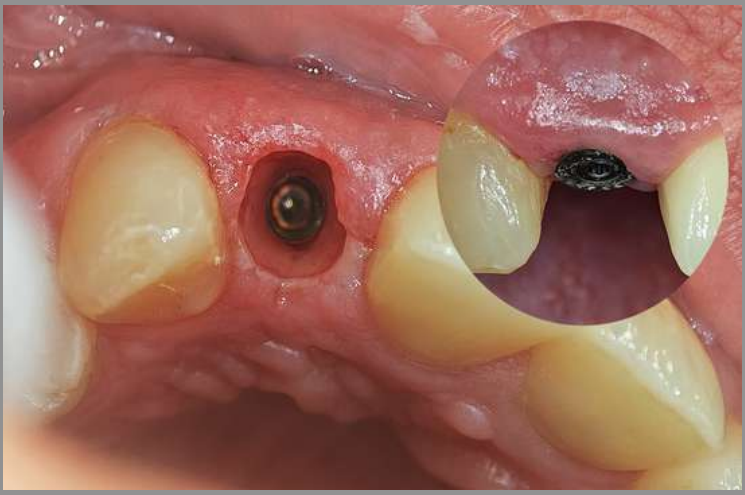Pilot drill location



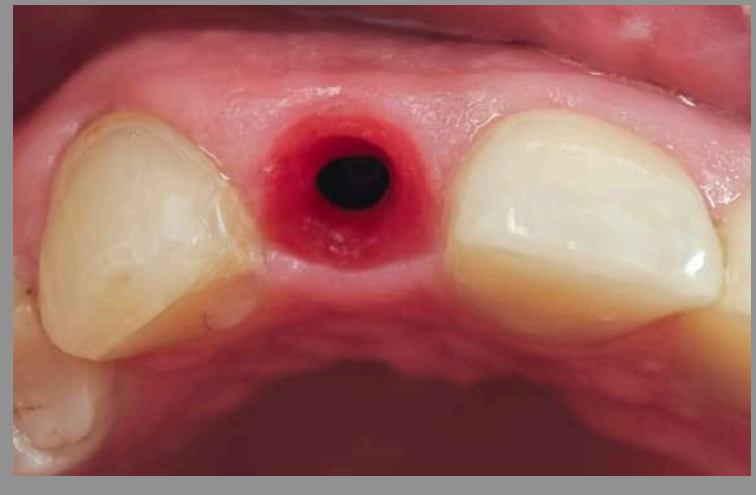Implant R 3514 for apical bone engagement beyond the socket for predictable primary stability and immediate loading



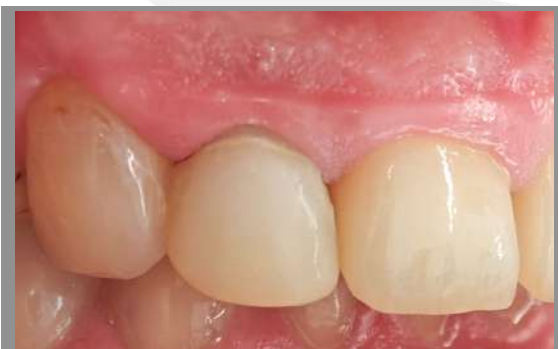Post operative panoramic xray with healing abutment



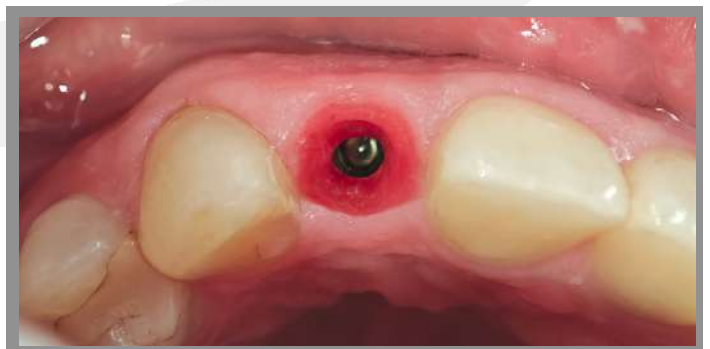
Healing Abutment removed with healthy soft tissue healing and architecture



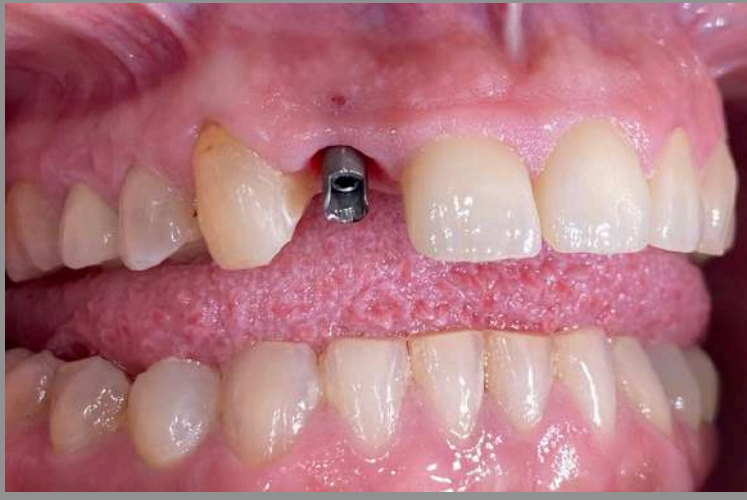Emergence profile developed with Provisional prosthesis



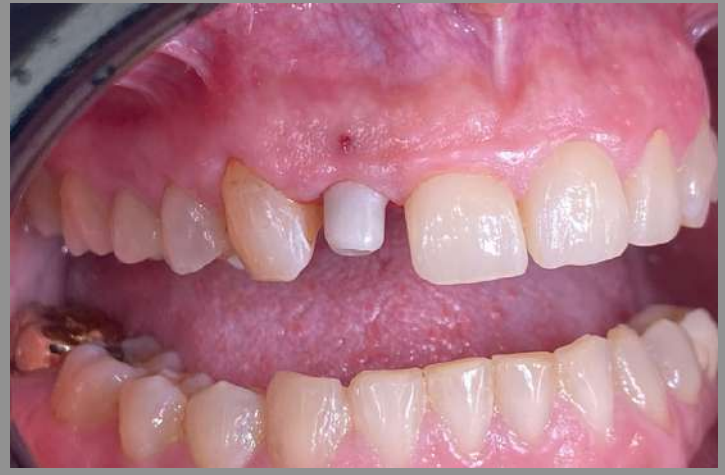Provisional in place to develop papillary fill and achieve ideal emergence profile



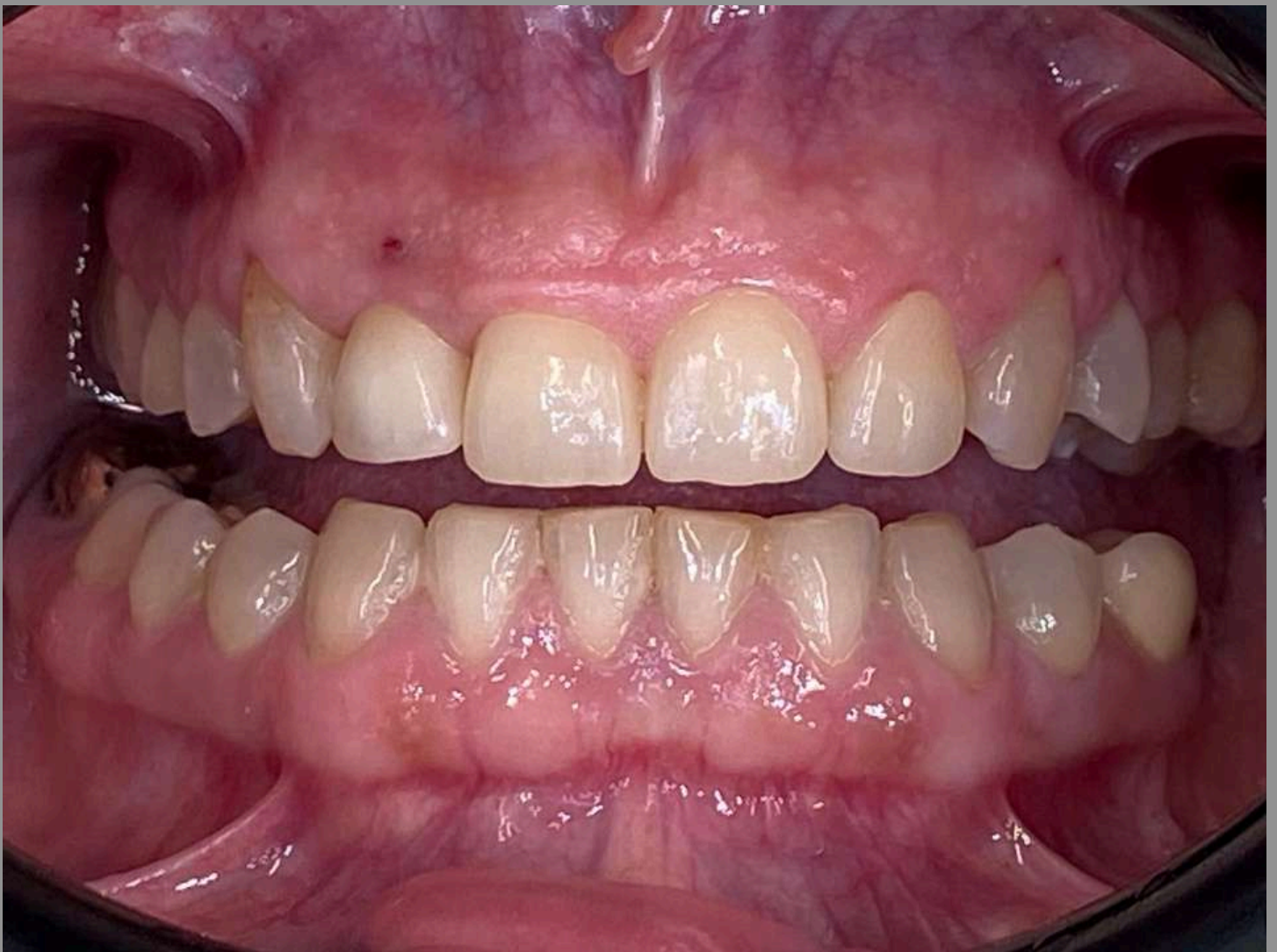Scanning of Emergence profile for Final Prosthesis




Scanning of PCO abutments for direct scanning



PCO abutments with Zirconia coping



Final restoration with zirconia crowns in patient



# Clinical cases

## ROOTT R

### Clinical situation

The patient was referred by a general dentist - D26 with periapical lesion and subgingival palatal caries. The tooth had a hopeless prognosis and required extraction with immediate implant placement.

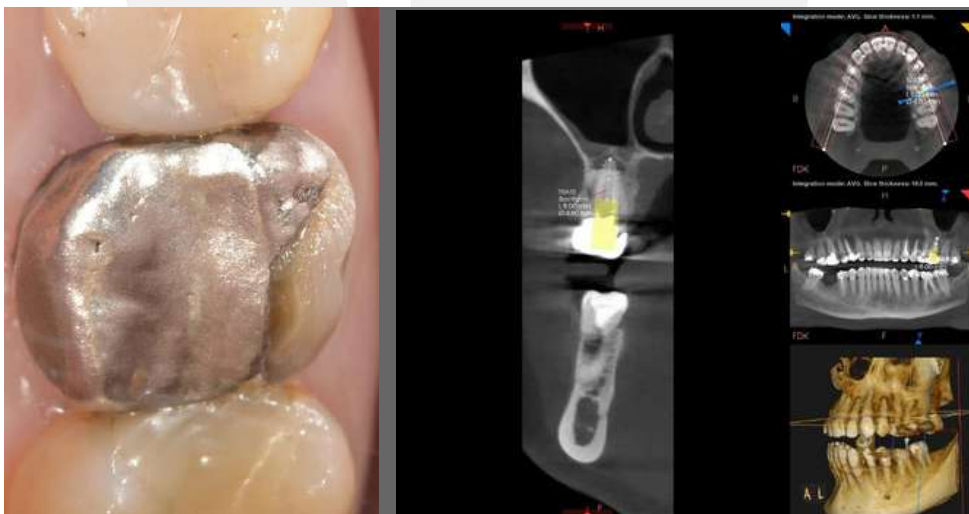Gender: Female  
Age: 35

Atraumatic extraction using root separation preserved the interradicular septum and surrounding tissues. A ROOTT implant (4.2 × 8 mm) was placed in a prosthetically driven position using osseodensification, enhancing bone density and achieving strong primary stability.

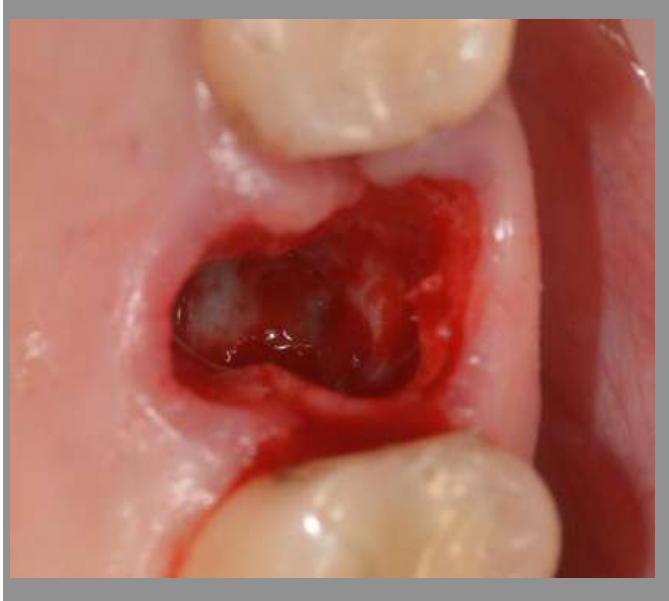

### Dr. Vladislavs Ananjevs DDS, PhD


- Implantologist & Prosthodontist based in Latvia
- Founder & Chief Dentist at REMEDIUM Clinic
- Specialist in implant rehabilitation and restorative dentistry
- Strong focus on prosthodontics and long-term implant outcomes
- PhD in bone regeneration and bioceramic materials
- Research-driven approach to bone biology and implant stability
- Combines clinical practice with scientific innovation in implantology
- Active in advancing modern implant and restorative workflows
- Expertise in evidence-based implant solutions for complex bone conditions



INITIAL SITUATION AND PLANNING



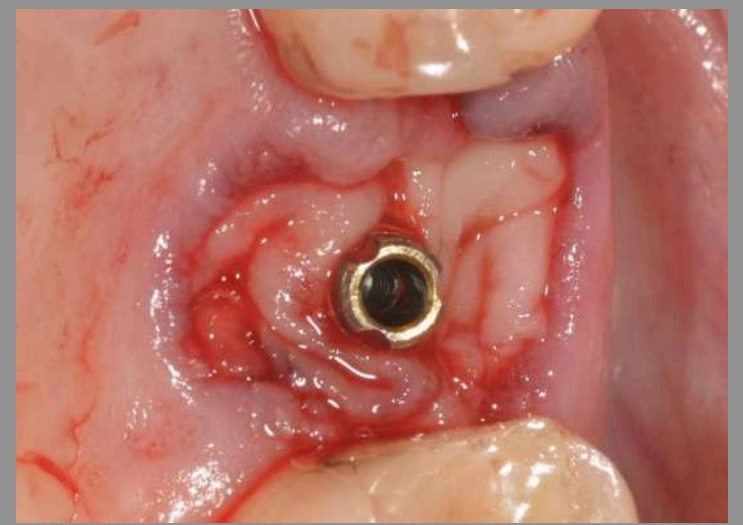
Atraumatic extraction of D26, socket curettage.



R4208



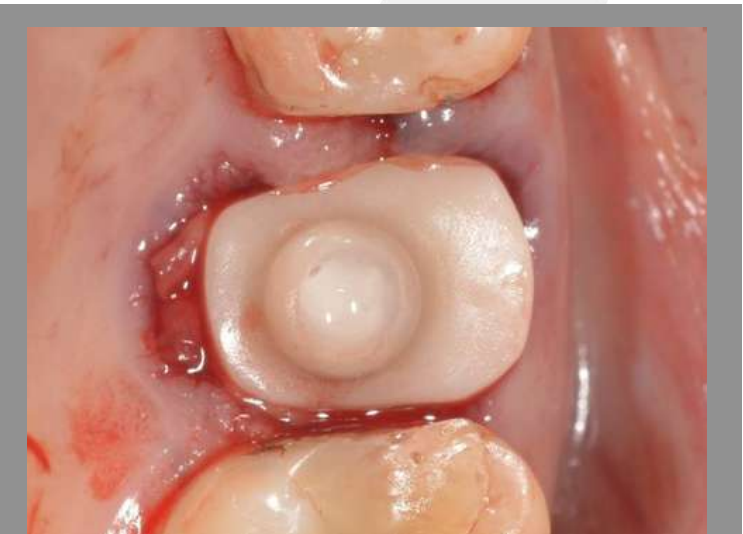Conometric Abutment



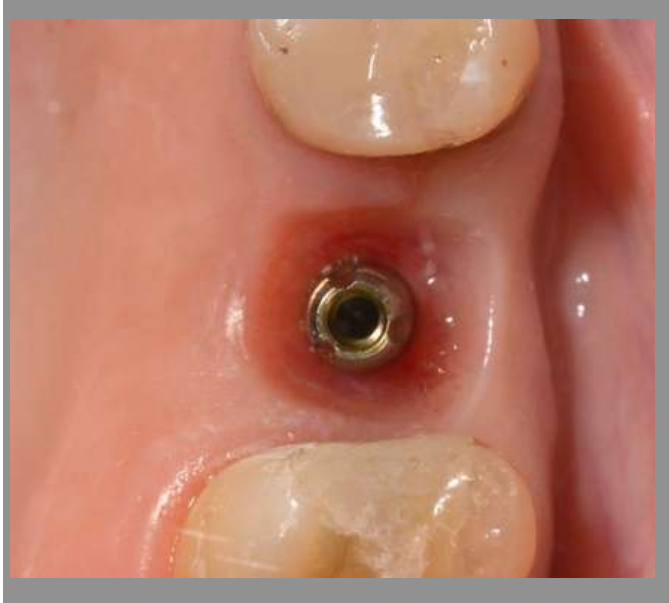Immediate implant placement ( - High primary stability achieved: 40 Ncm; ISQ 74. Socket sealing using Advanced Platelet-Rich Fibrin (A-PRF).



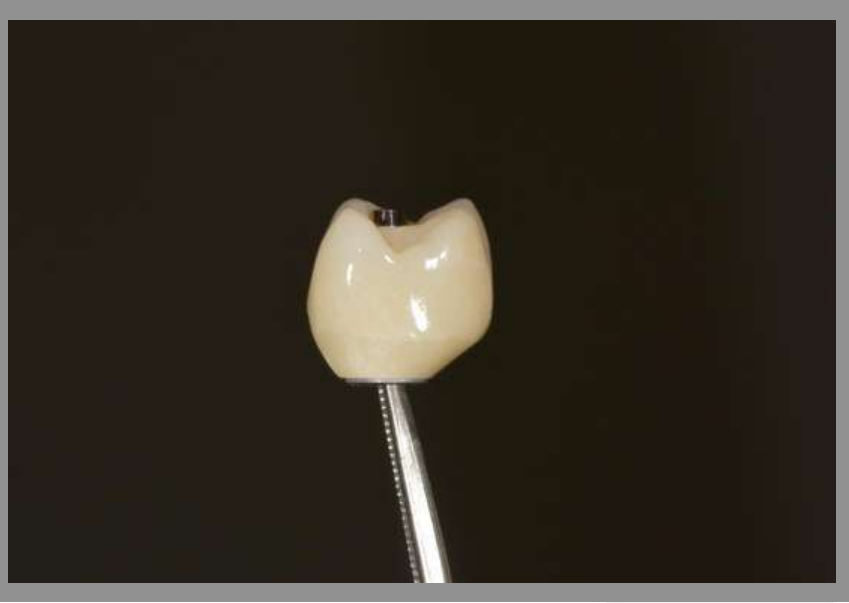Individual zirconia gingiva former fixation.



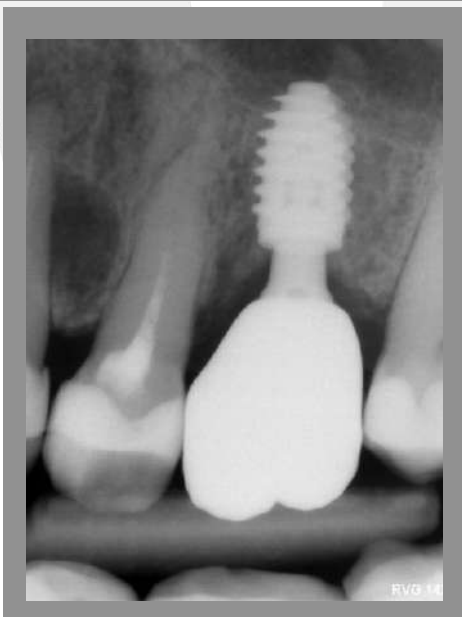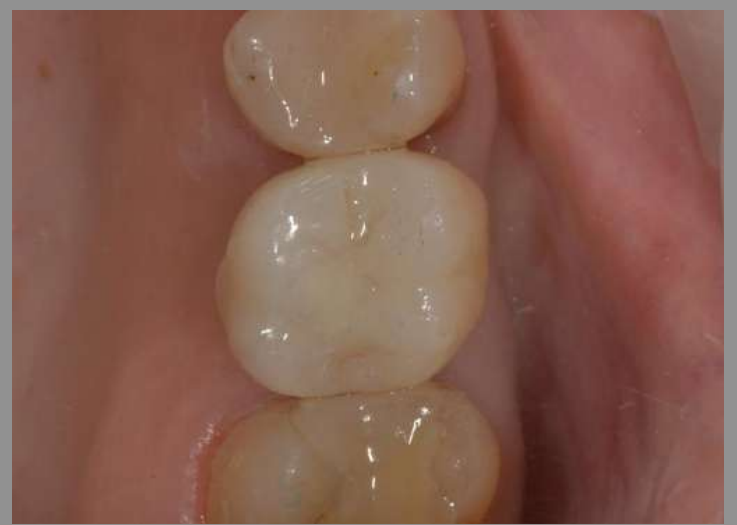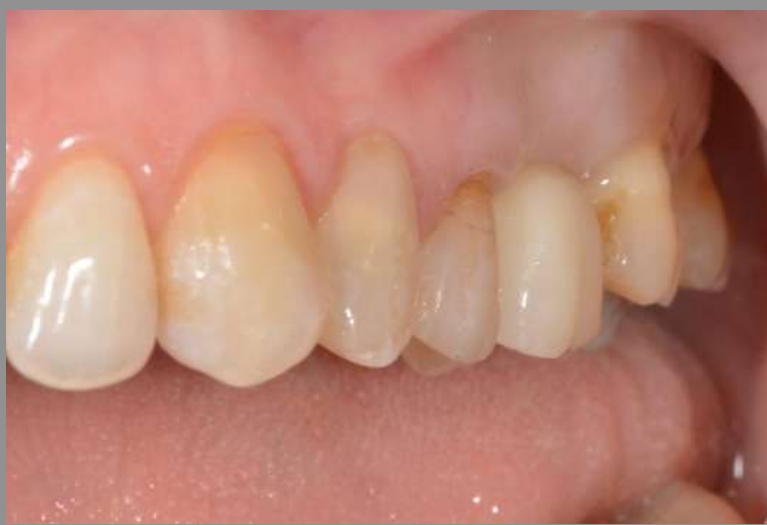Immediate placement of conometric abutment following the Zero Bone Loss and One Abutment One Time concept.



Emergence Profile after 2 months of Healing



Cement-free & Screw-less Crowns on Conometric Caps



A final monolithic zirconia crown was fabricated and delivered with conometric fixation, ensuring a cement-free and screw-free prosthetic solution.

FINAL RESULT



## Clinical cases

# ROOTT R

### Clinical situation

The patient presented with failing maxillary dentition requiring full-arch extraction and rehabilitation.

Gender: Male

Age: 65

All remaining maxillary teeth were extracted, followed by placement of six ROOTT R implants in an All-on-6 configuration—two anterior and four posterior—to maximize A-P spread and ensure stable load distribution.

ROOTT Multi-Unit Abutments were installed to create a screw-retained platform, and an immediate fixed temporary prosthesis was delivered, restoring function and aesthetics on the same day.

After a 4–6 month osseointegration period, final impressions were taken using a hybrid workflow, followed by placement of the definitive full-arch prosthesis.

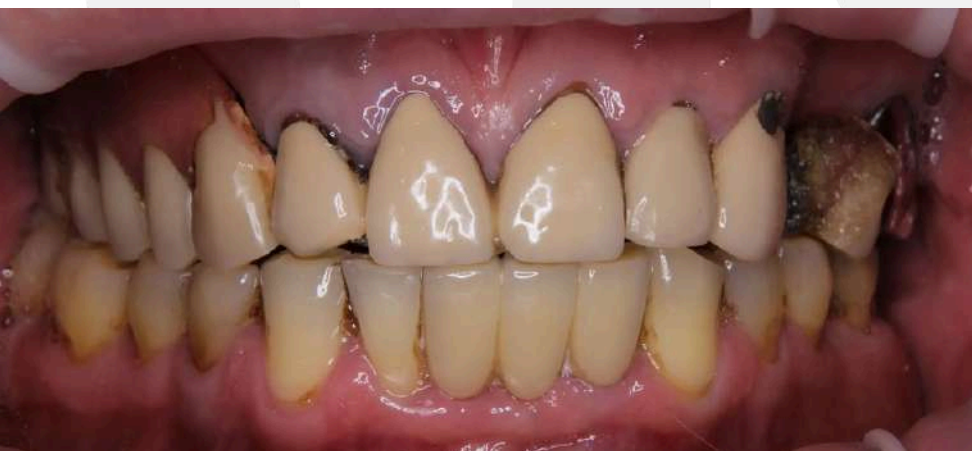The procedure was completed successfully without complications.



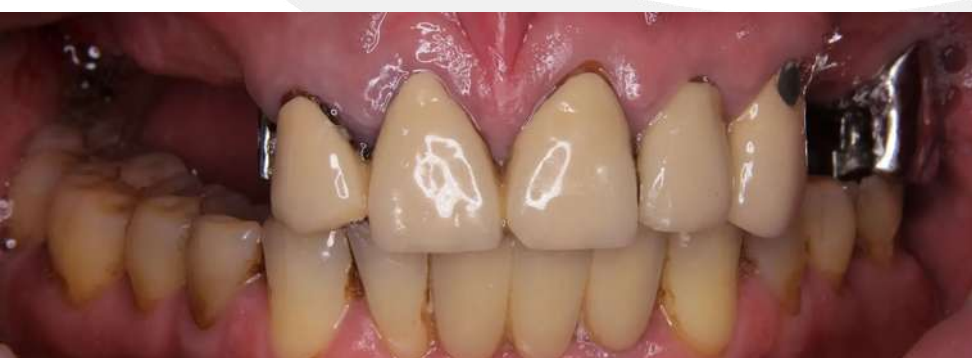## Dr. Roman Novichenkco

### DMD

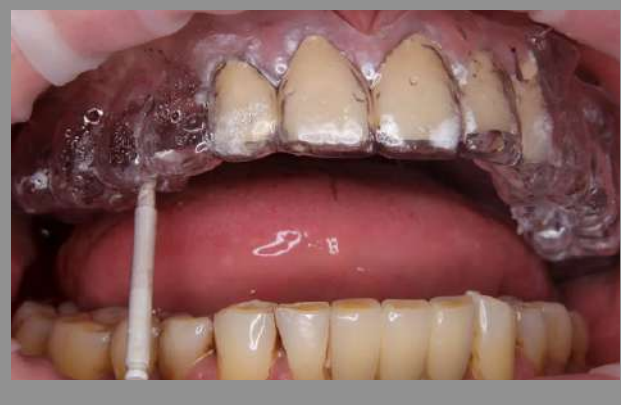- Implant Surgeon & Functional Dentist with 20+ years of experience
- Expert in neuromuscular dentistry and TMJ treatment
- Specialist in implantology, prosthetics, and complex oral rehabilitation
- Strong focus on functional occlusion and full-mouth reconstruction
- Founder & Clinic Owner since 2009
- Mentor at TRATE and active researcher in Open Dental Community
- Trained at Stavropol Medical Academy and Boston Institute of Neuromuscular Dentistry
- Creator of MistTens devices and Hummingbird software



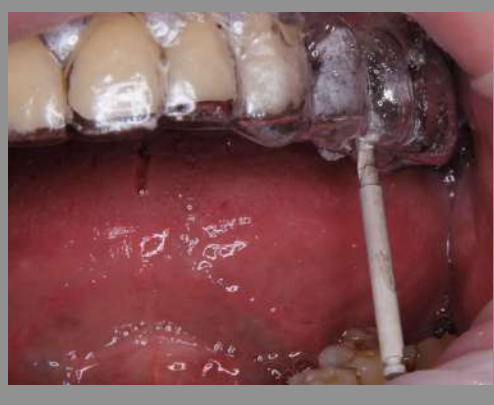Pre-Operative Picture with Posterior RPD



Pre-Operative Picture with Posterior Edentulous area



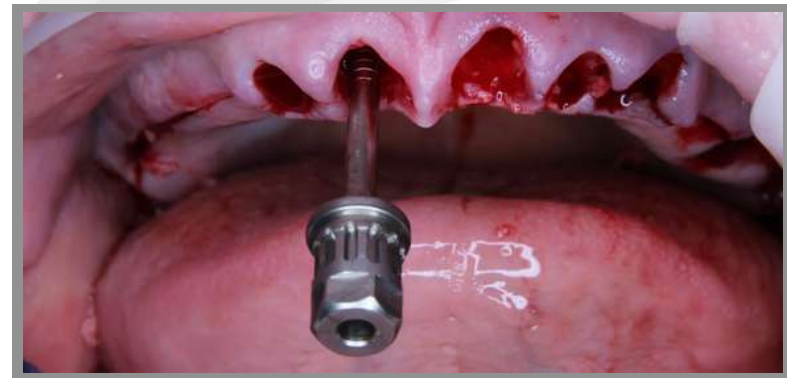Intra-operative picture with Conventional Surgical Guide Right side



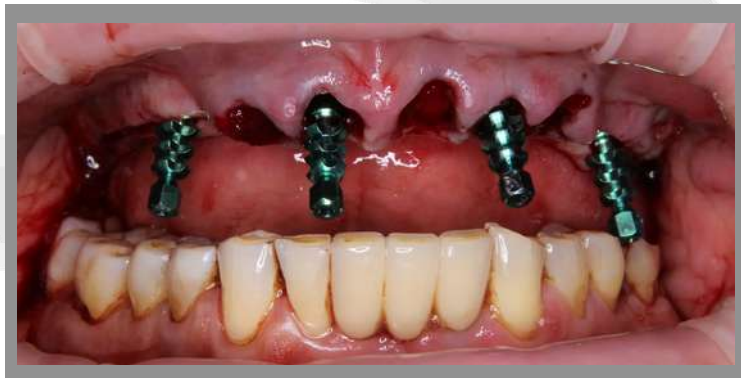Intra-operative picture with Conventional Surgical Guide Left Side



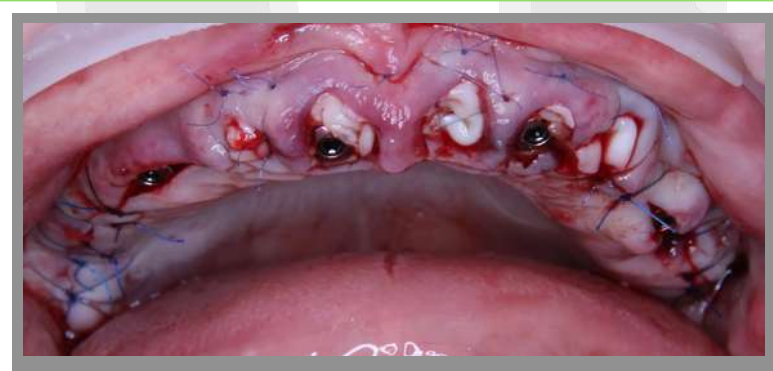Conventional Guide with vacuum formed tray



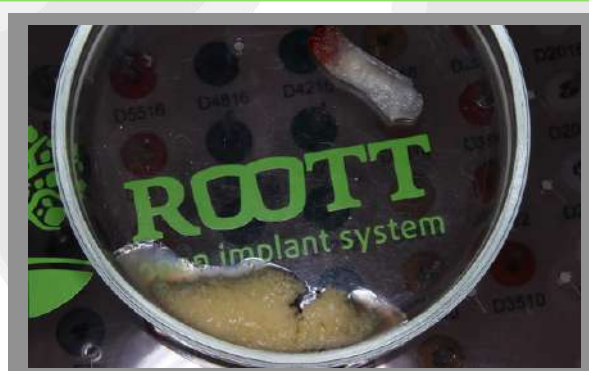Intra operative picture of implant placed in 11 region



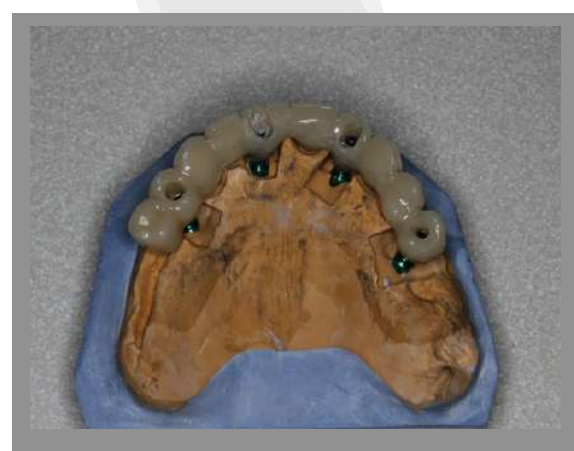
Intraoperative picture of ROOTT R implants placed with immediate implant level impressions



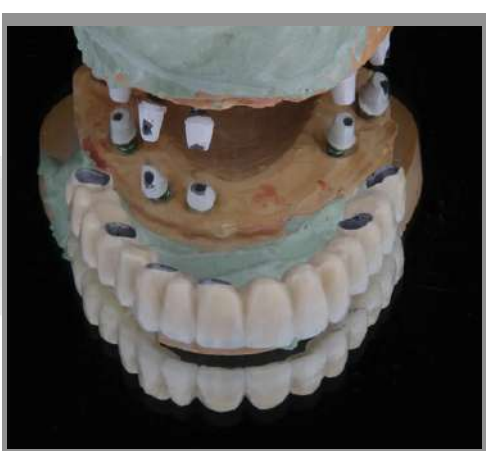Surgical site closure with PRF membrane and healing abutments .



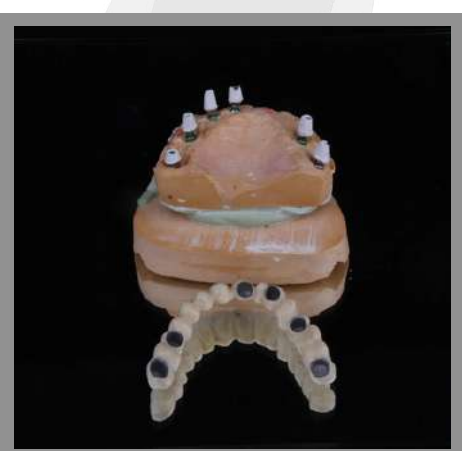PRF Membrane with sticky bone graft



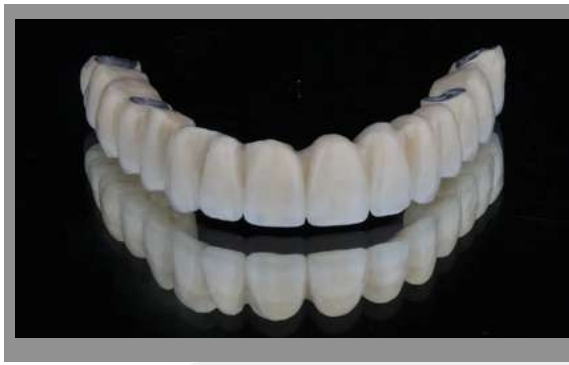Prosthesis with Hybrid Abutments and full arch PFM crowns



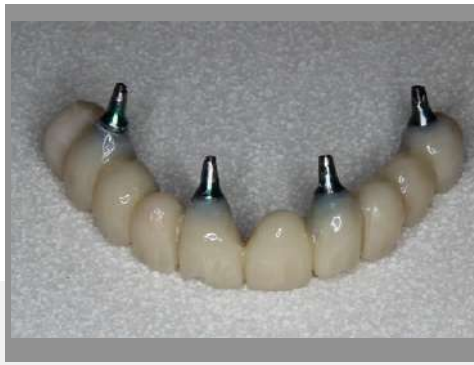Prosthesis with Hybrid Abutments and full arch PFM crowns



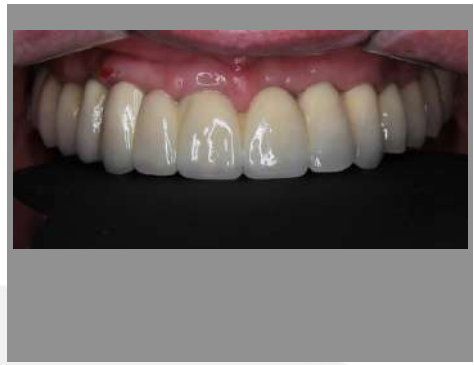Prosthesis with Hybrid Abutments and full arch PFM crowns on model ALL on 4



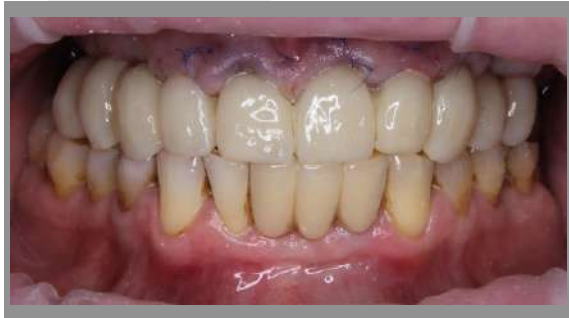ALL on 4 PFM prosthesis suprastructure



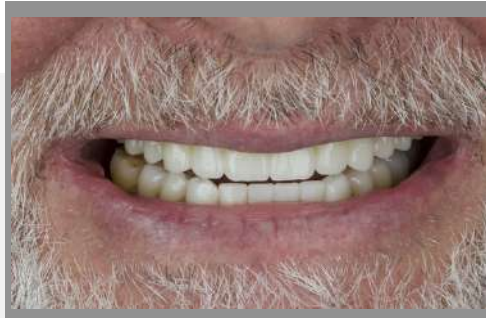ALL on 4 PFM prosthesis cementd on hybrid abutments



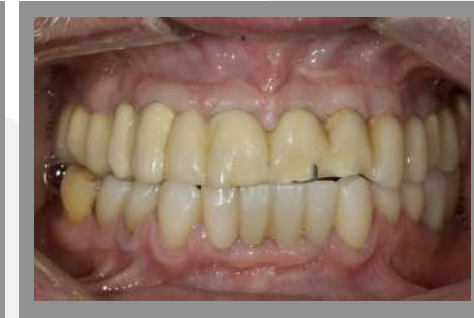ALL on 4 PFM prosthesis cementd on hybrid abutments in patient fornt view



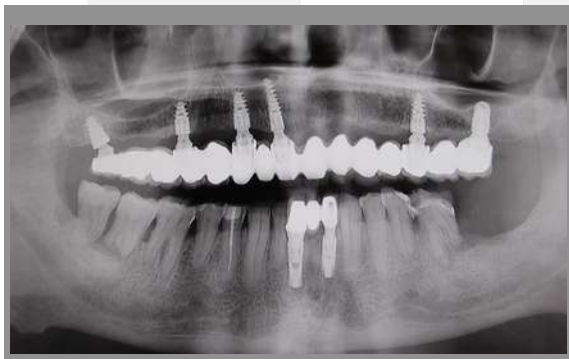
Intra oral ALL on 4 PFM prosthesi in patient Bite view



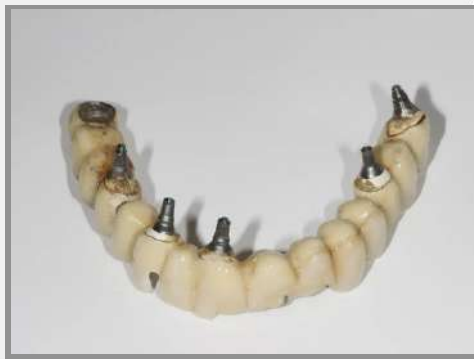Intra oral ALL on 4 PFM prosthesi in patient Bite view



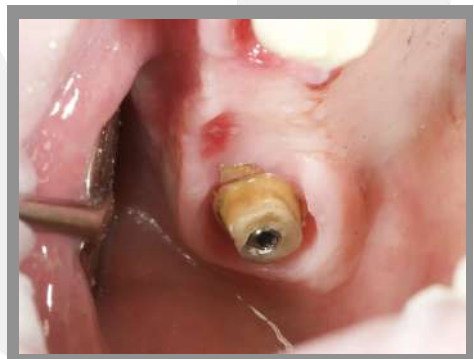Chipping of PFM crowns in the anterior 21/22 area after 10 years of function



Post- operative xray Implant failed in the 22 region after years of fuction due to bruxism



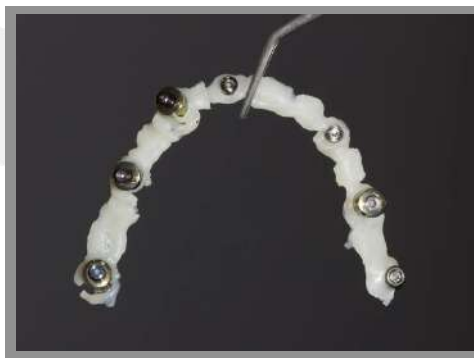Old PFM prosthesis removed from function



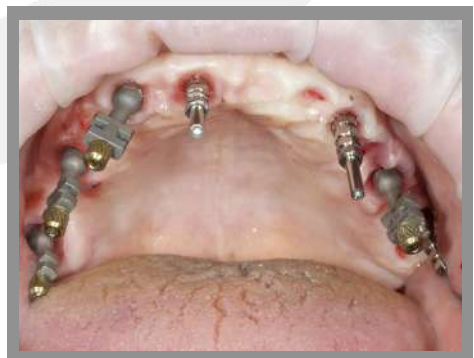Old Hybrid abutment in plcae with cement overretained in the sulcus



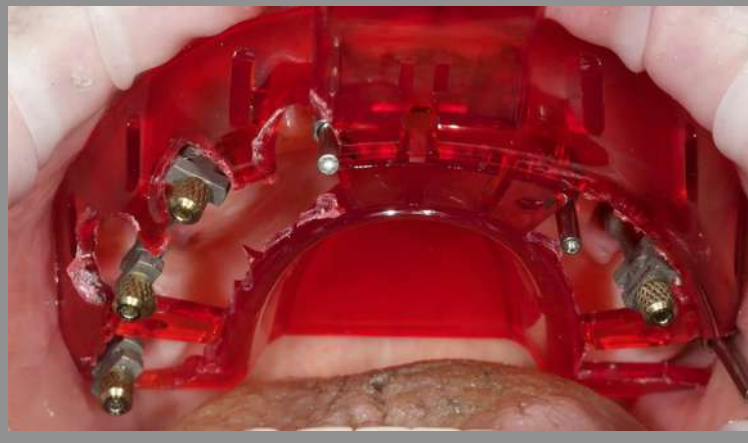
Healing abutment Jig with composite



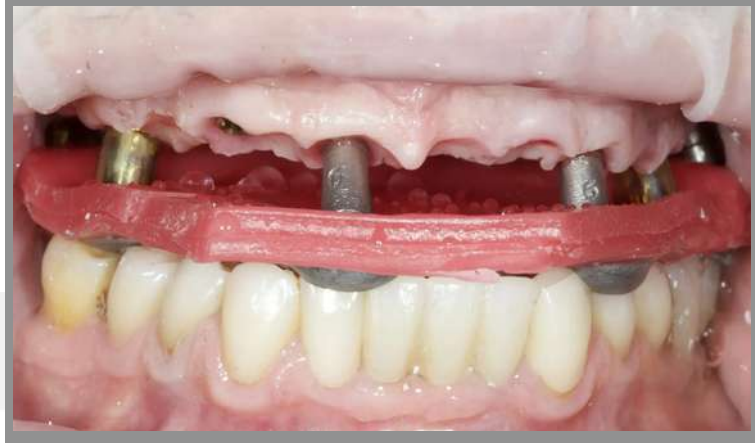Healing abutments in place on Multi unit abutments to reasses the situation



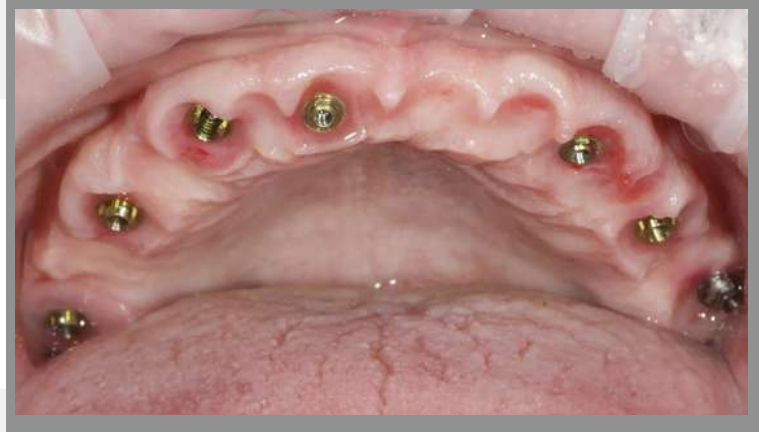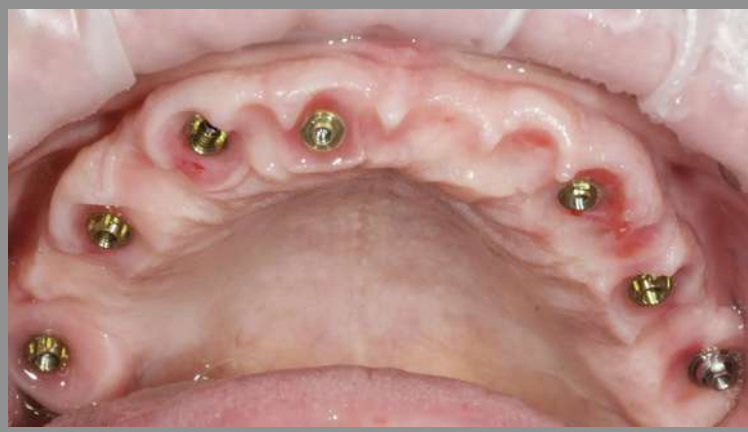Open tray impression at multi unit level in place



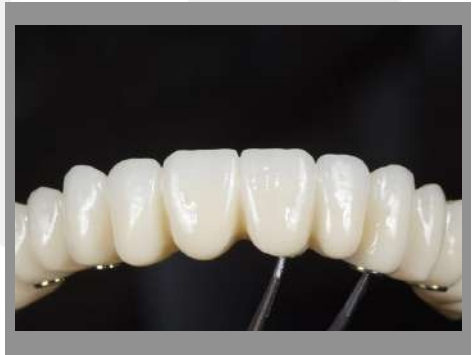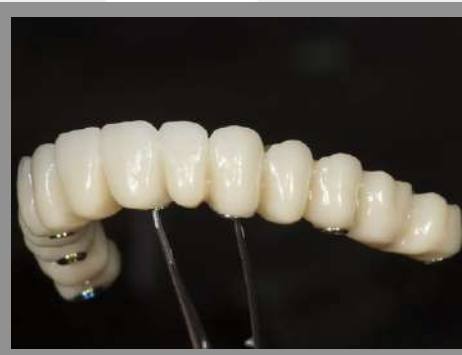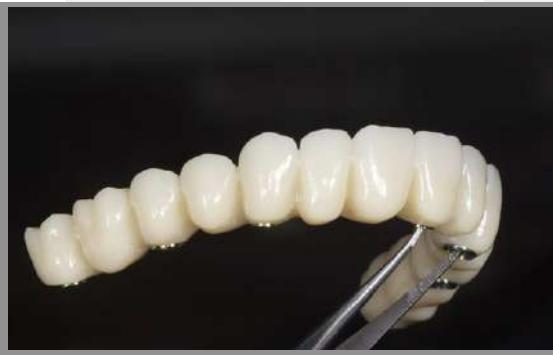Tray with windows for open tray impression technique



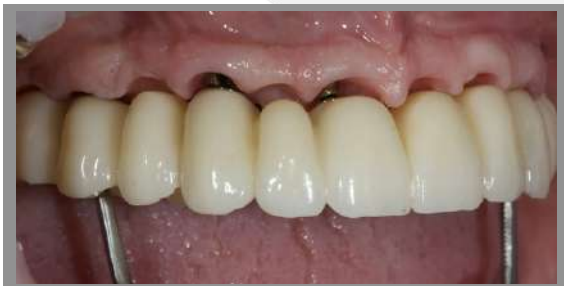Verification Jig trial to evaluate passivity of the fit



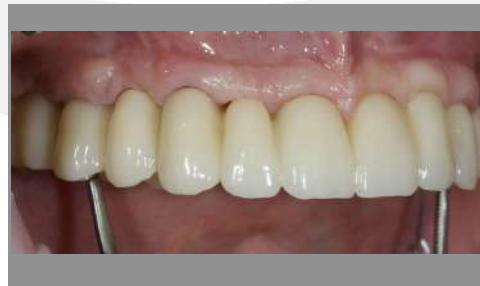Multi unit autments in position and tissue conditioning



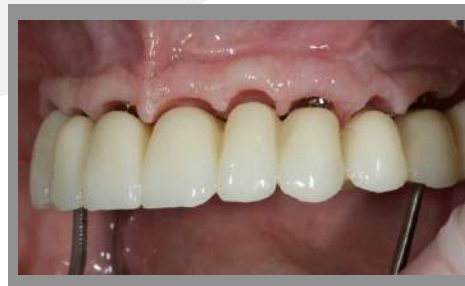FP1 FULL arch zirconia prosthesis on Multi unit Ti base PCOMR



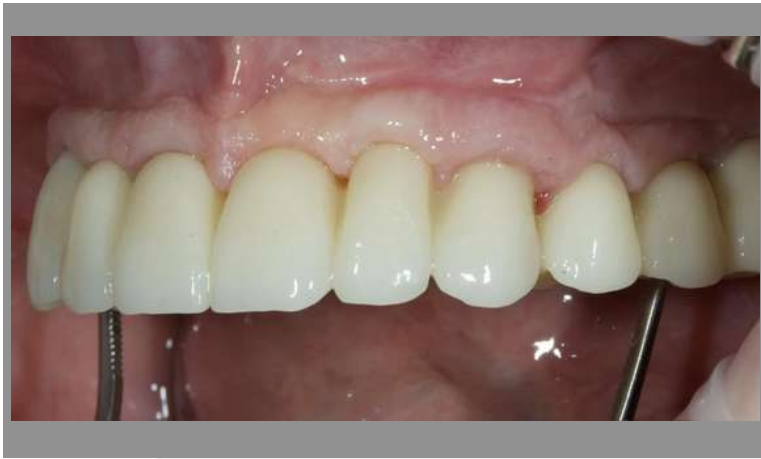Full arch zirconia FP1 prosthesis in patient with tissue conditioning right quadrant



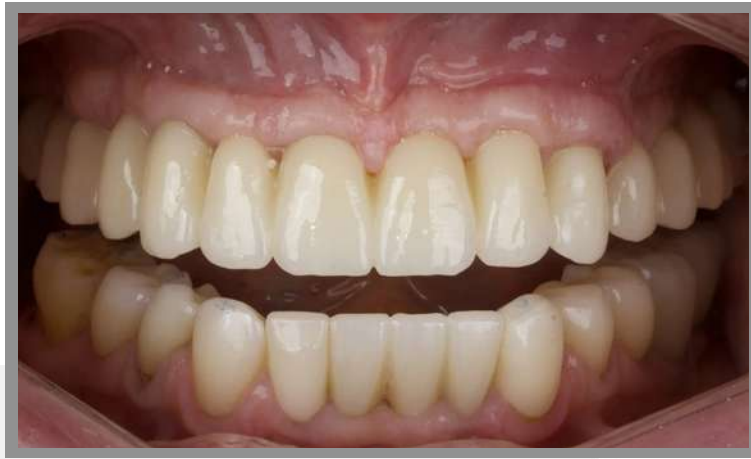Full arch zirconia FP1 prosthesis in patient right quadrant



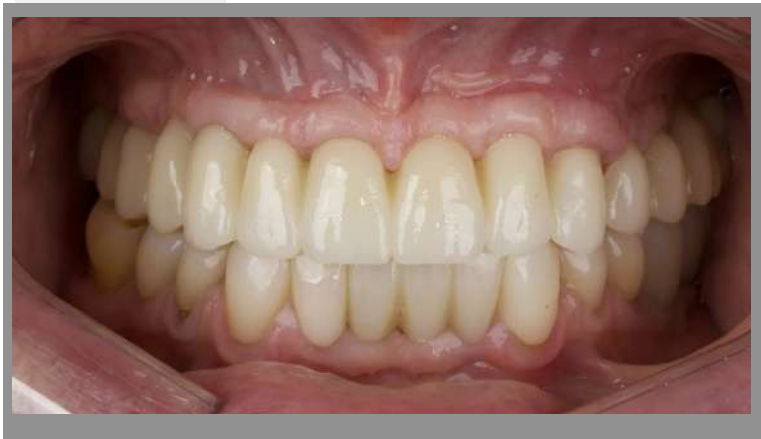Full arch zirconia FP1 prosthesis in patient with tissue conditioning Left quadrant



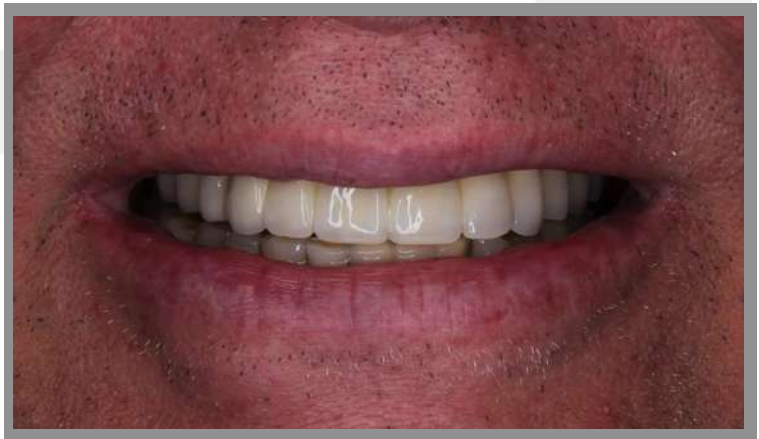Full arch zirconia FP1 prosthesis in patient left quadrant



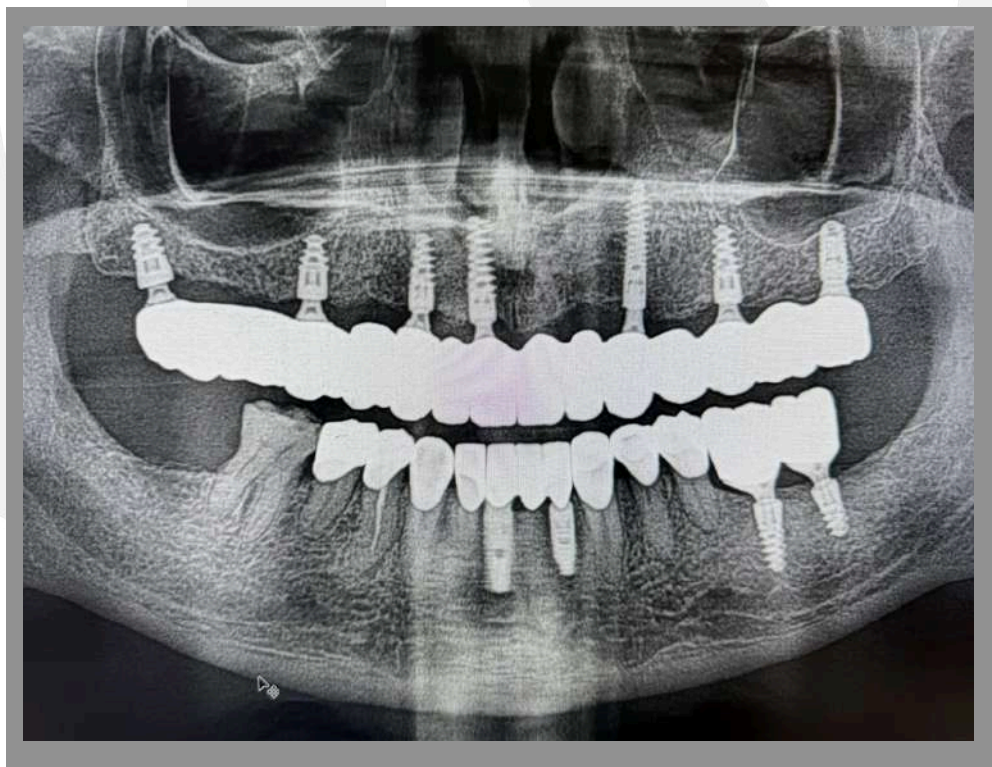Full arch zirconia FP1 prosthesis in patient Frontal view



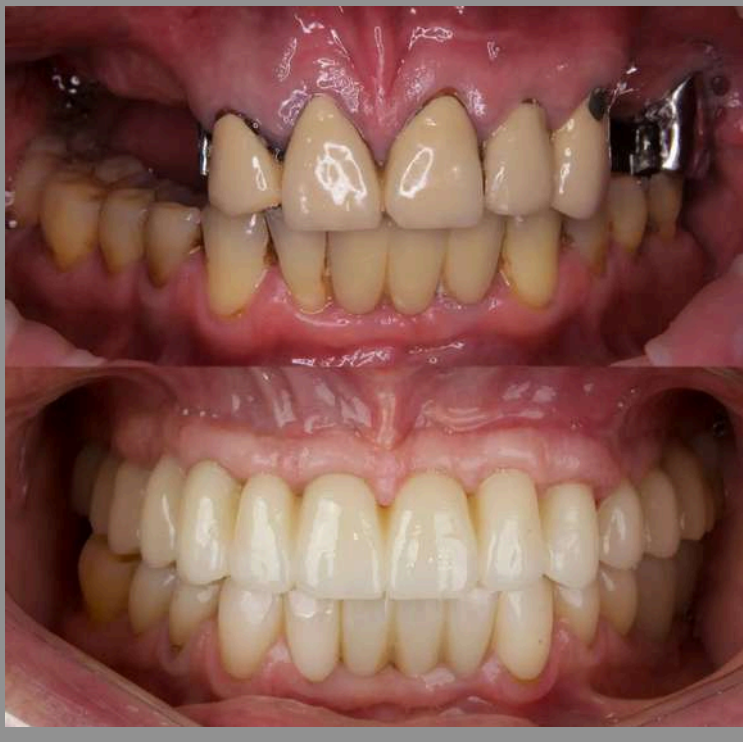Full arch zirconia FP1 prosthesis in patient Bite view



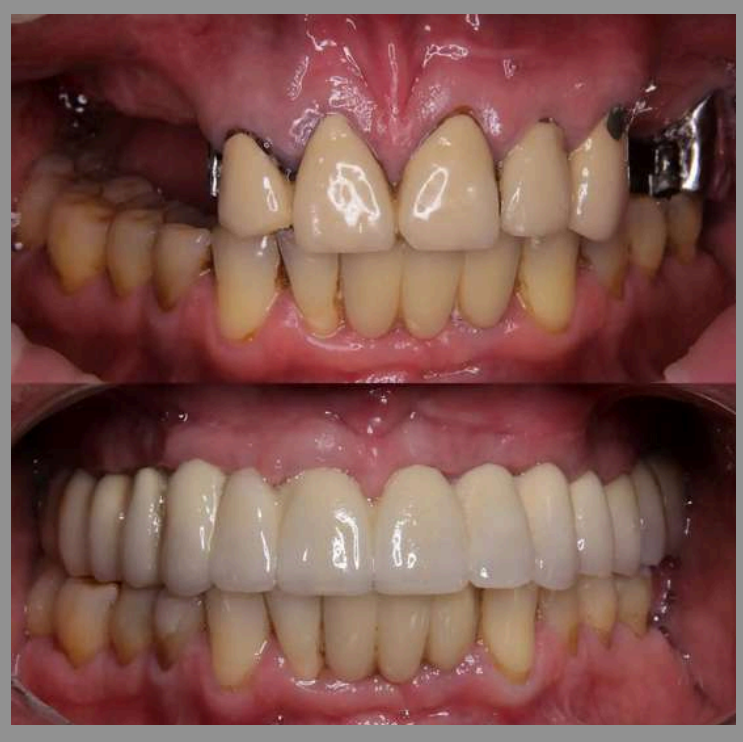Full arch zirconia FP1 prosthesis in patient smile



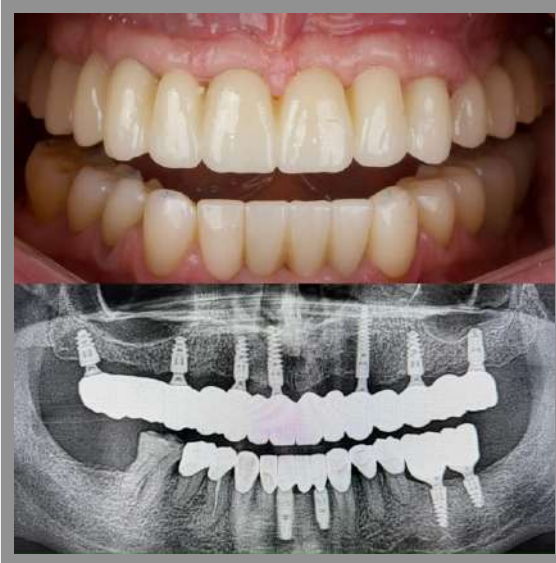Post Oprative Xray Full Arch ALL on 7



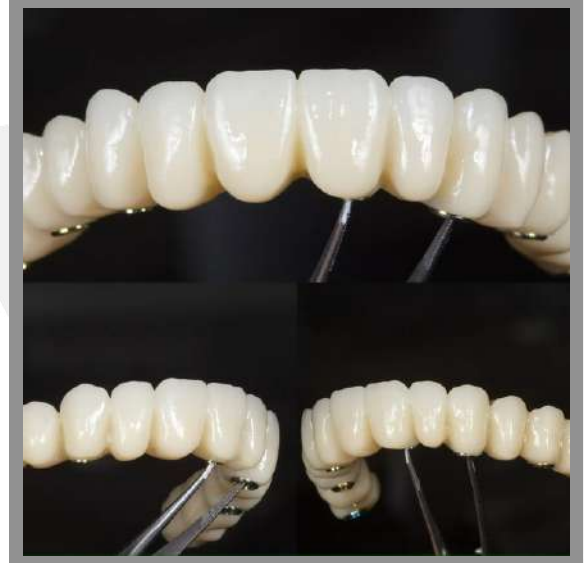Cover Zirconia Before & After



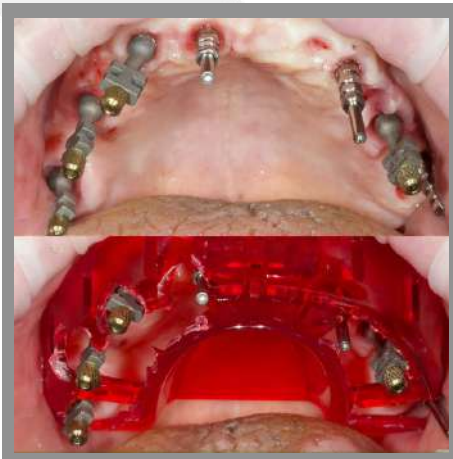Cover PFM Crowns



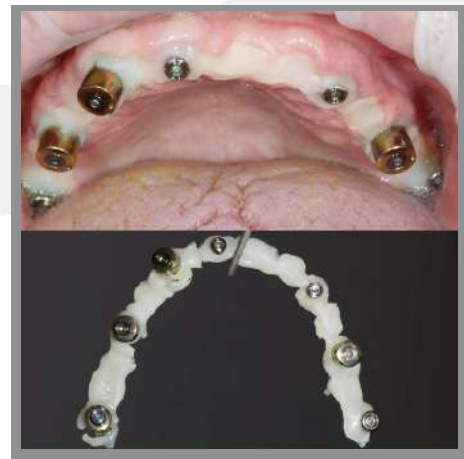Final with Xray



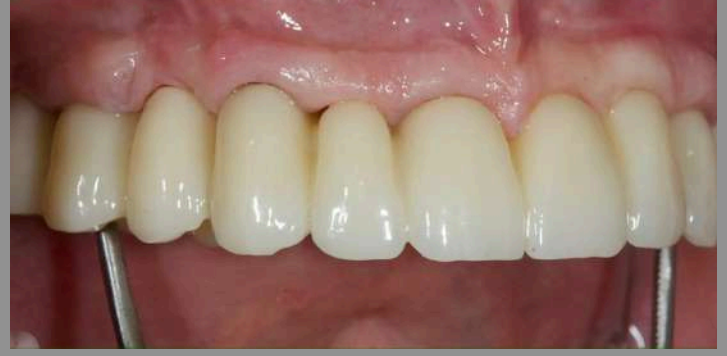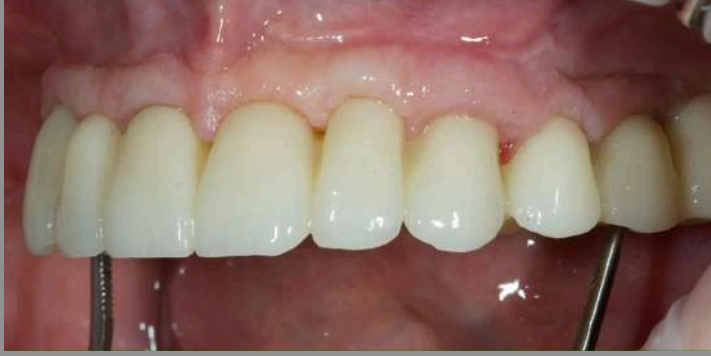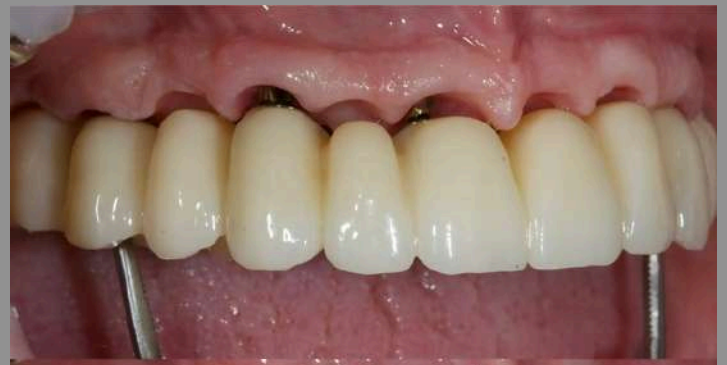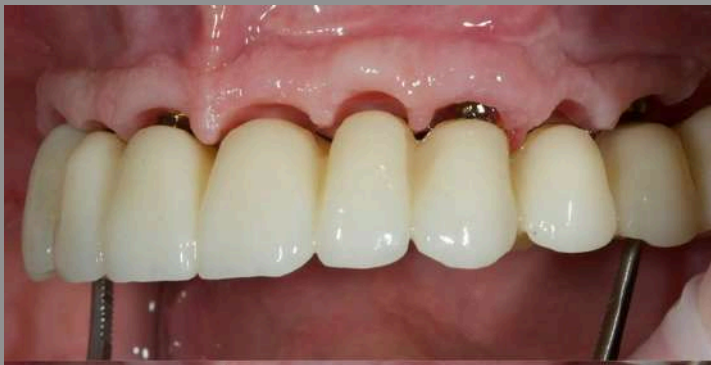Prosthesis Full Zirconia



Impression

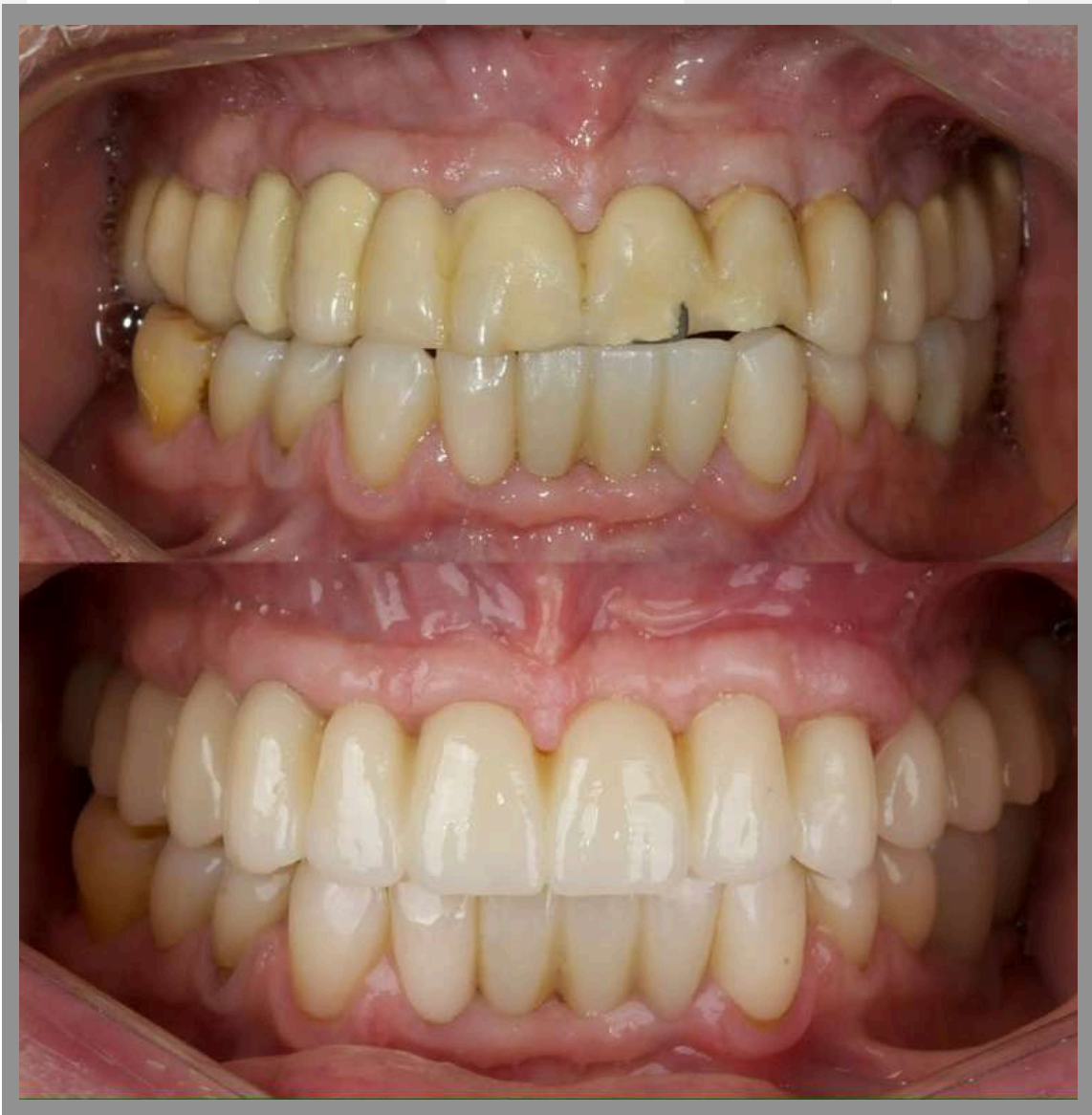

Healing Verification



Soft tissue Architecture left side

Soft tissue Architecture right side



Transition from Old PFM to New Zirconia



## Clinical cases

# ROOTT M P

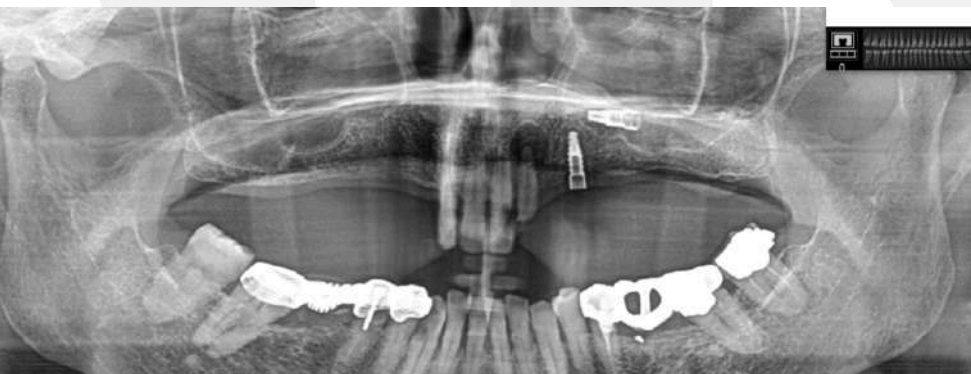### Clinical situation

The patient presents with a failing full-arch implant restoration in the maxilla. The case is complicated by highly pneumatized maxillary sinuses and severe posterior bone resorption, leaving inadequate vertical bone height for standard posterior implant placement.

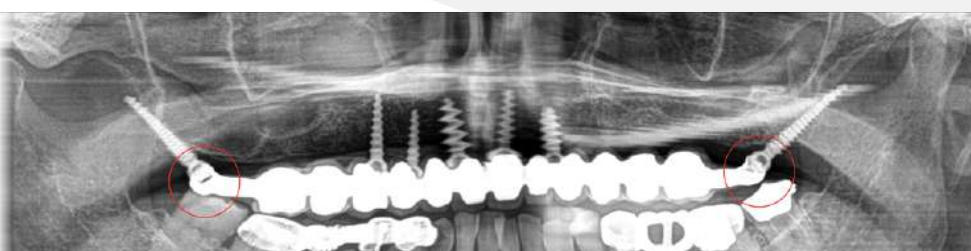Gender: Female

Age: 65

Removal of the failed implants and immediate full-arch rehabilitation using a combination of anterior implants and pterygoid implants. ROOTT M implants are placed in the anterior maxilla, while ROOTT P (Pterygoid) implants are placed bilaterally in the posterior maxilla. By engaging the dense cortical bone of the pterygomaxillary region, the surgical team successfully bypasses the pneumatized sinuses, entirely avoiding the need for a sinus lift or bone grafting procedure. This strategic placement maximizes the anteroposterior (A-P) spread, providing optimal posterior support and allowing for a stable final prosthesis completely free of distal cantilevers.



Preoperative clinical Situation Panoramic Xray with failed previous implants & Sinus Pneumatization

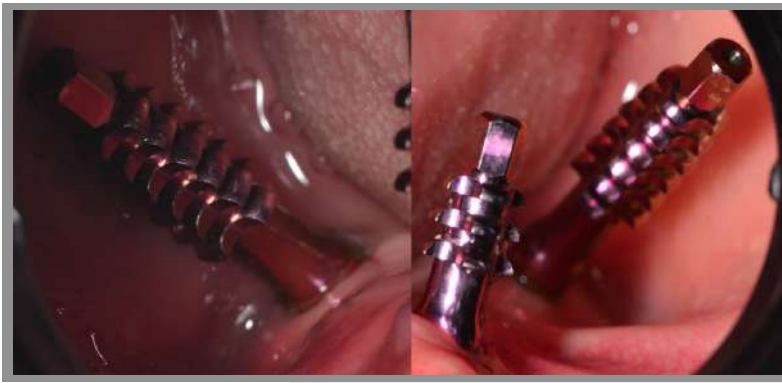

Postoperative panoramic xray post implant placement

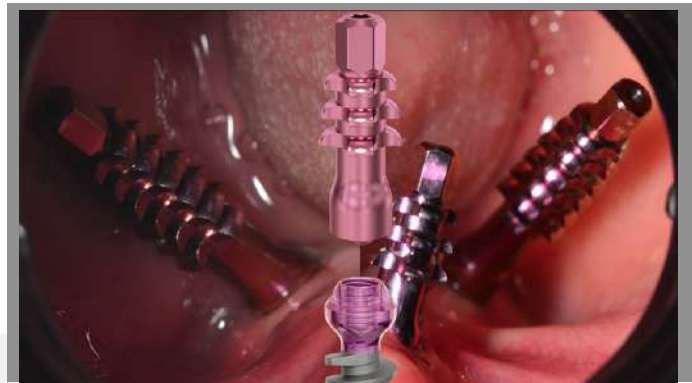

## Dr. Mohamed Babouche DMD


- Implantologist & Dentist based in El Eulma, Sétif, Algeria
- Active clinician focused on implant dentistry and oral rehabilitation
- Specialist in immediate implantation, fixed restorations, and esthetic implant solutions
- Strong focus on practical implant workflows and patient-centered outcomes
- International trainer in implantology through Babouche Asnane Academy
- Conducts hands-on training programs and beginner-to-advanced implant courses
- Associated with ROOTT implant education and clinical training initiatives
- Fluent in Arabic and French, working across diverse patient profiles



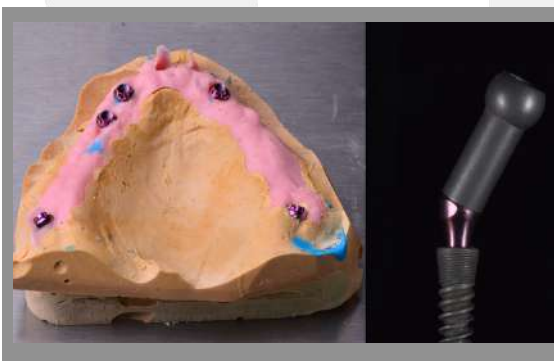Impression taking with TOM/TOML OPEN TRAY technique



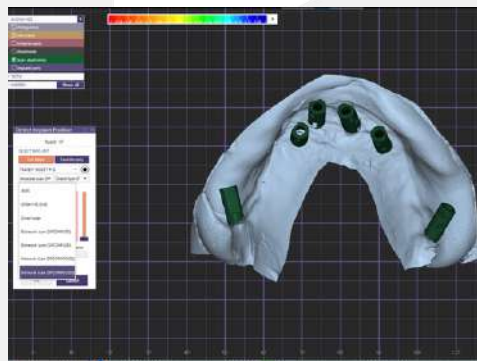
TOM and pink platform from pterygoid implants



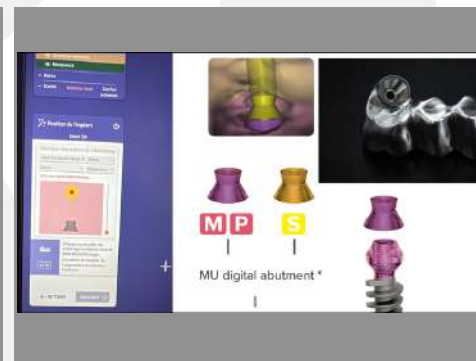Impression taken with Putty and light body with special try



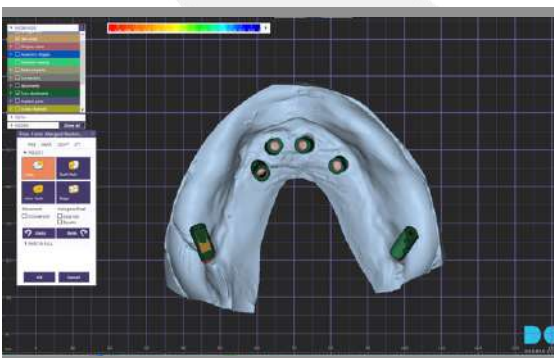
Master castfabrication with Lab scanbody SFCOM



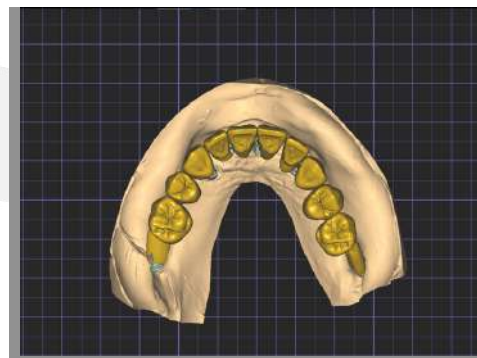
Library selection and scanbody matching with the implants and repective platforms



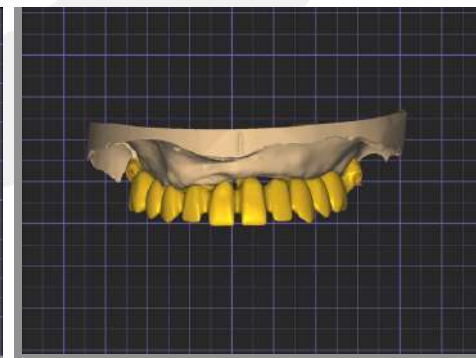
Selection of correct platform from ROOTT P and ROOTT S



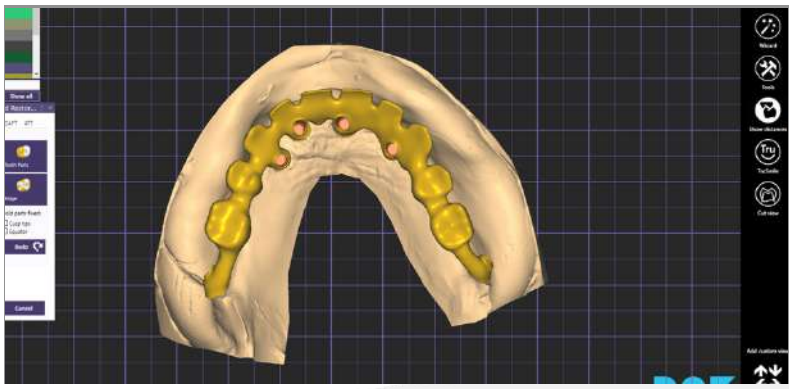
Library selection and scanbody matching with the implants and M platforms



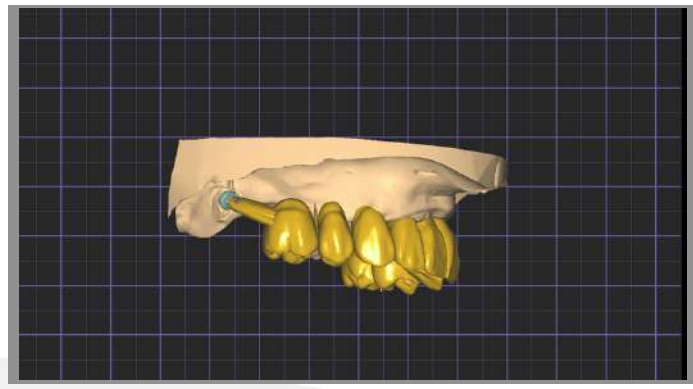
CAD Deisgn of the Prosthesis PFM



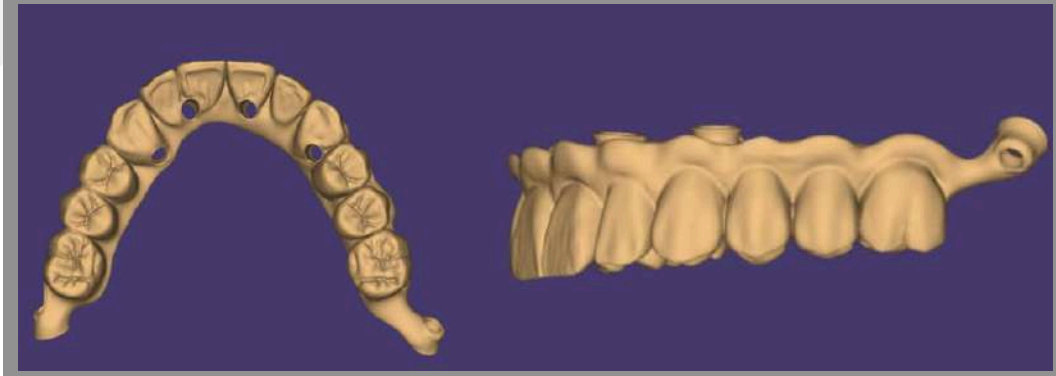
Front View Framework design with cut back space for porcelain



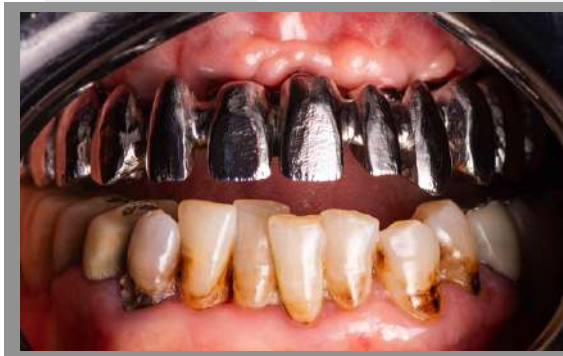Complete CAD Design of the Prosthesis PFM



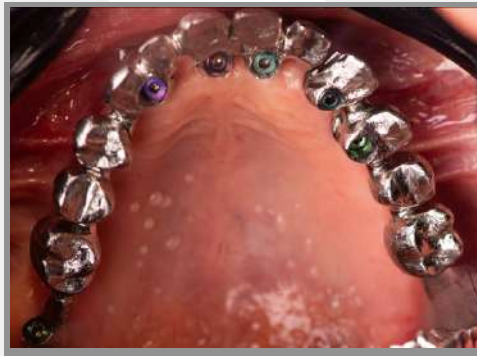Occlusal View Framework design with cut back space for porcelain



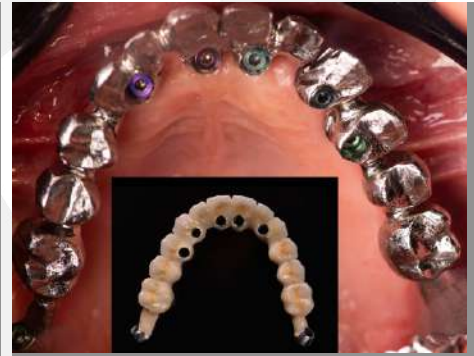Complete CAD Design of the Prosthesis PFM



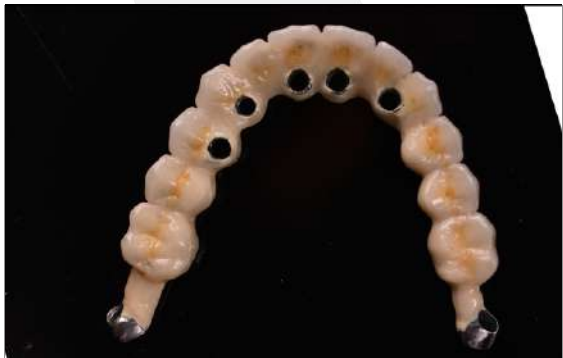Metal tryin of the framework front view



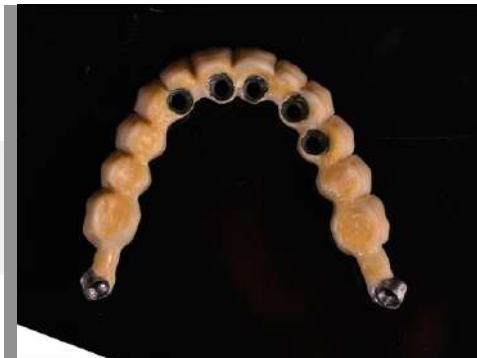Metal tryin of the framework occlusal view



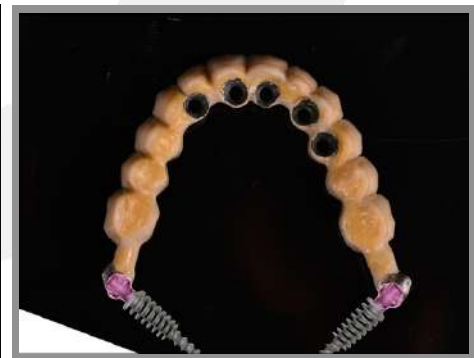Metal try in with full PFM restoration



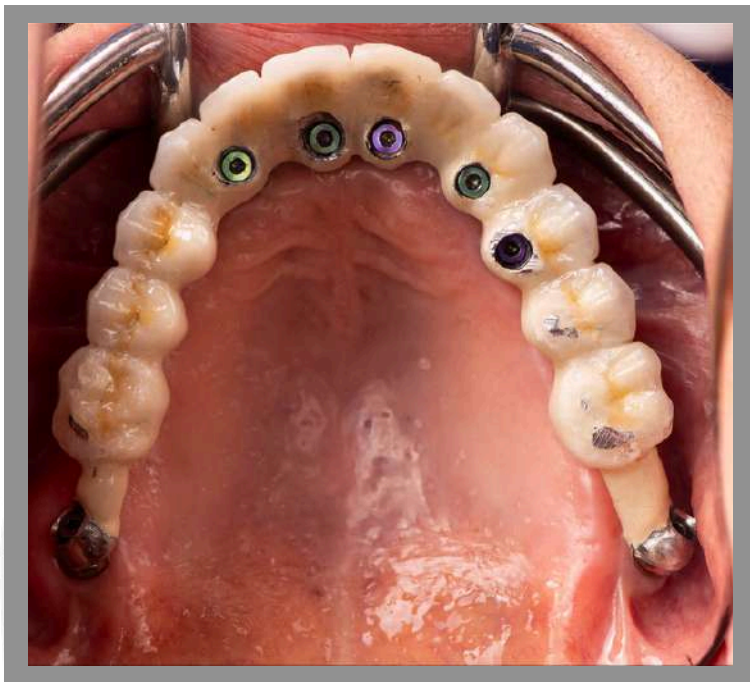PFM restoration with Occusal view



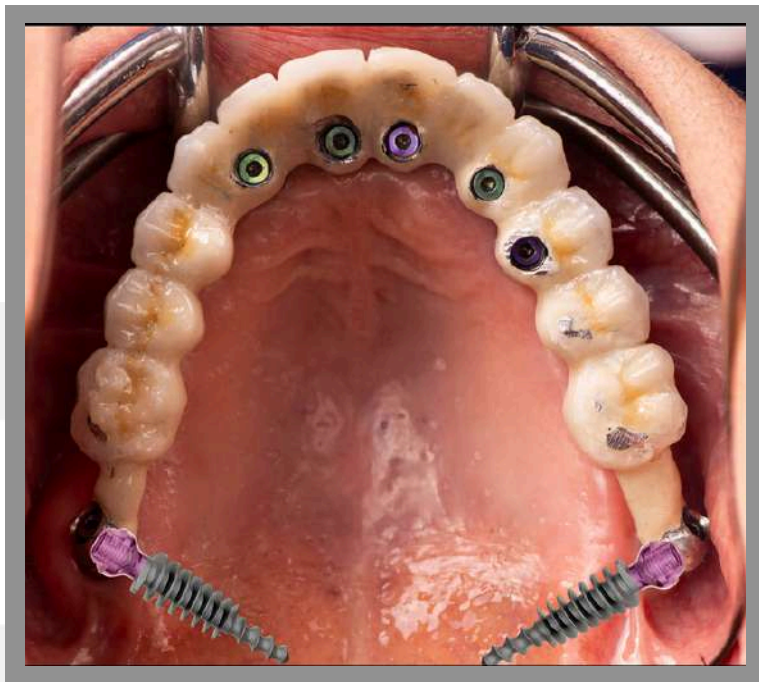PFM restoration with Occusal view



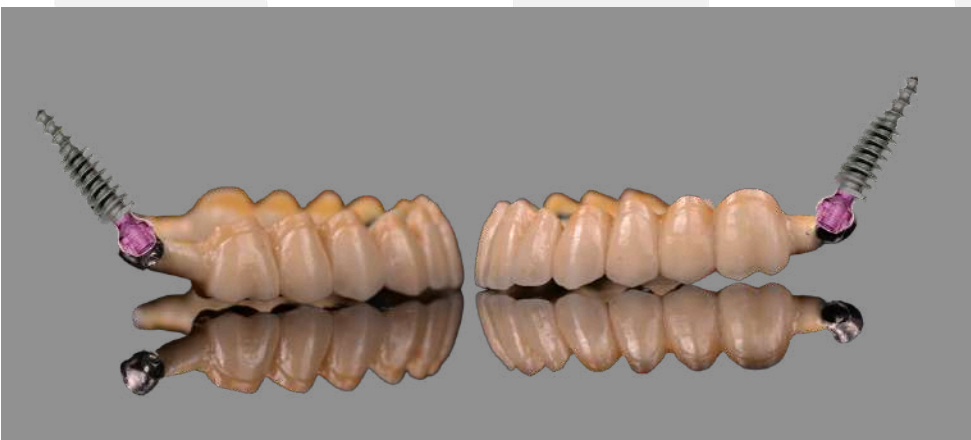
PFM restoration with Occusal view with ROOTT P ptergoid position in place



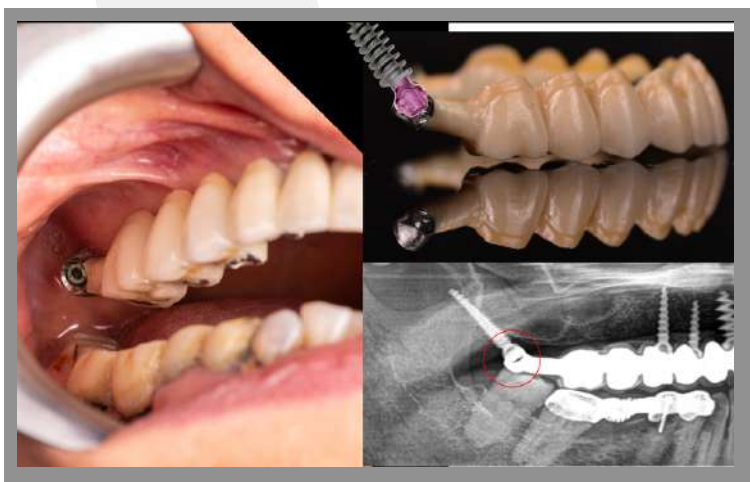
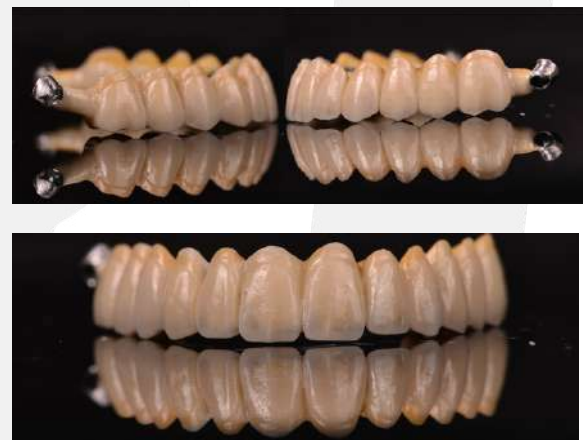PFM restoration with Occusal view in patient mouth



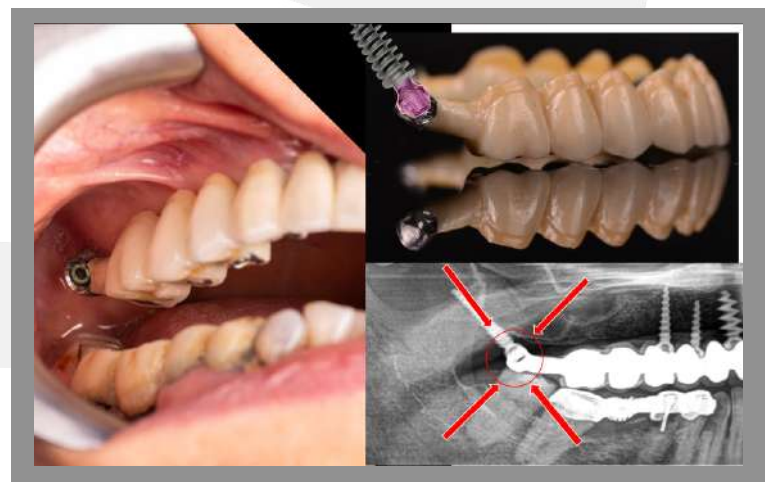
PFM restoration with Occusal view in patient mouth with ROOTT P pterygoid position



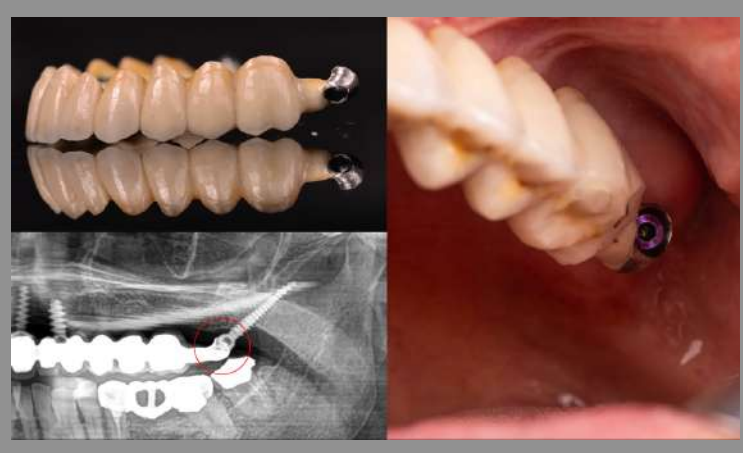
PFM Prosthesis lateral view



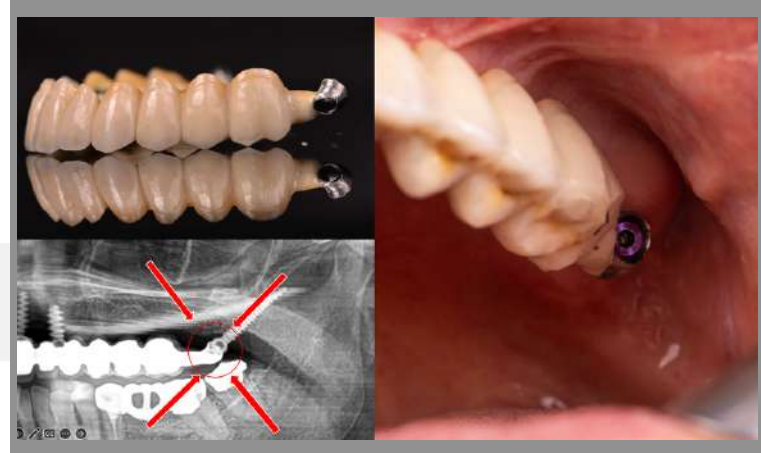
Prosthetic evaluation in patient with xray and Pterygoid implant location right Quadrant



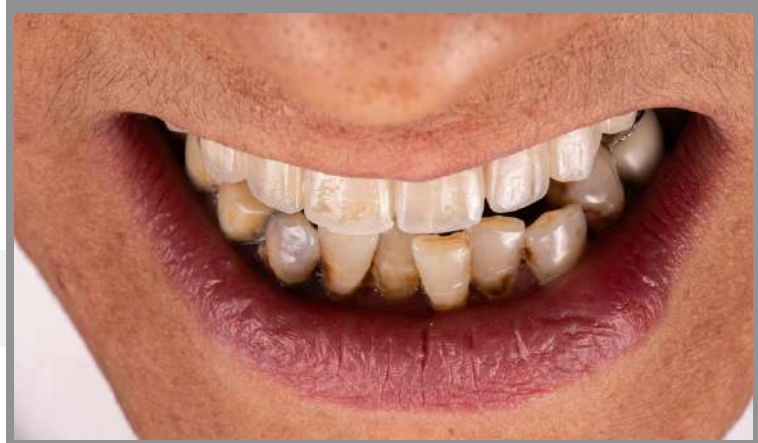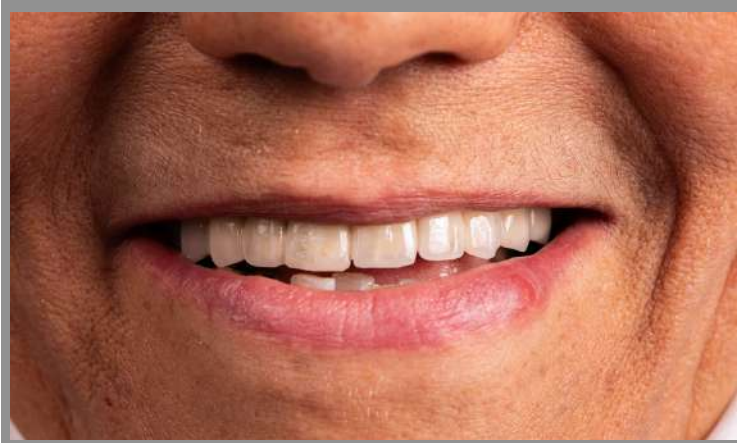Prosthetic evaluation in patient with xray and Pterygoid implant location right Quadrant fit evaluation



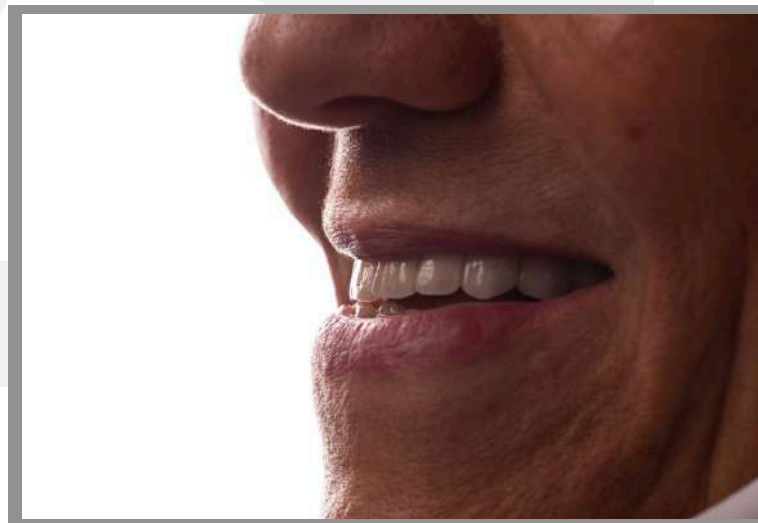
Prosthetic evaluation in patient with xray and Pterygoid implant location left Quadrant



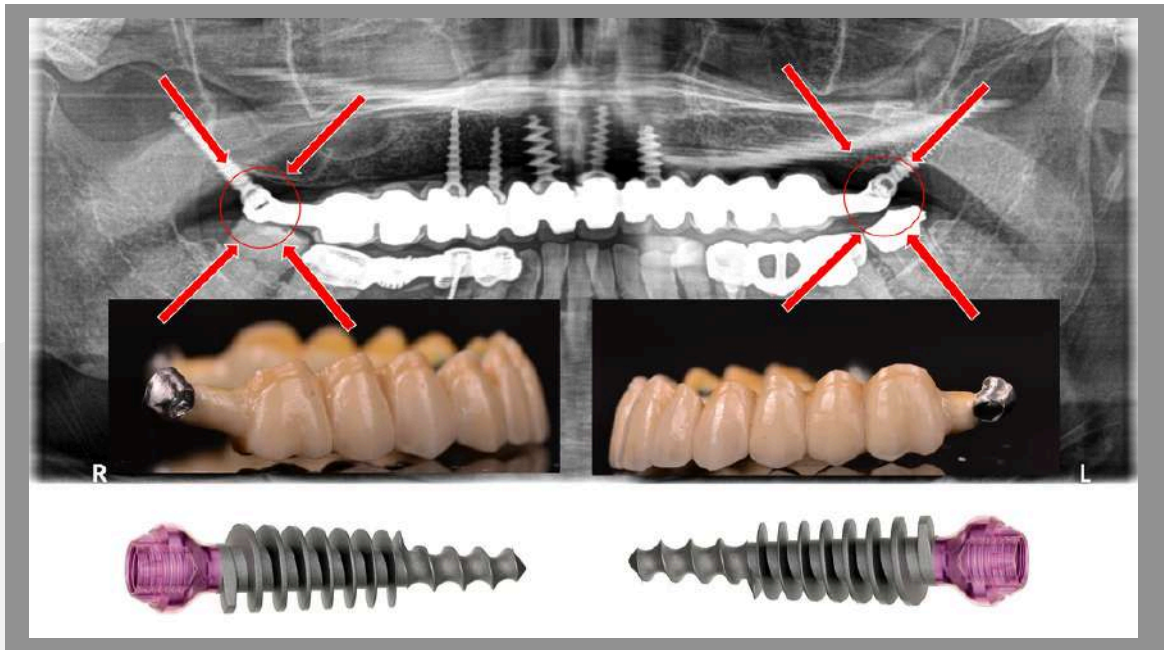
Prosthetic evaluation in patient with xray and Pterygoid implant location left Quadrant fit evaluation



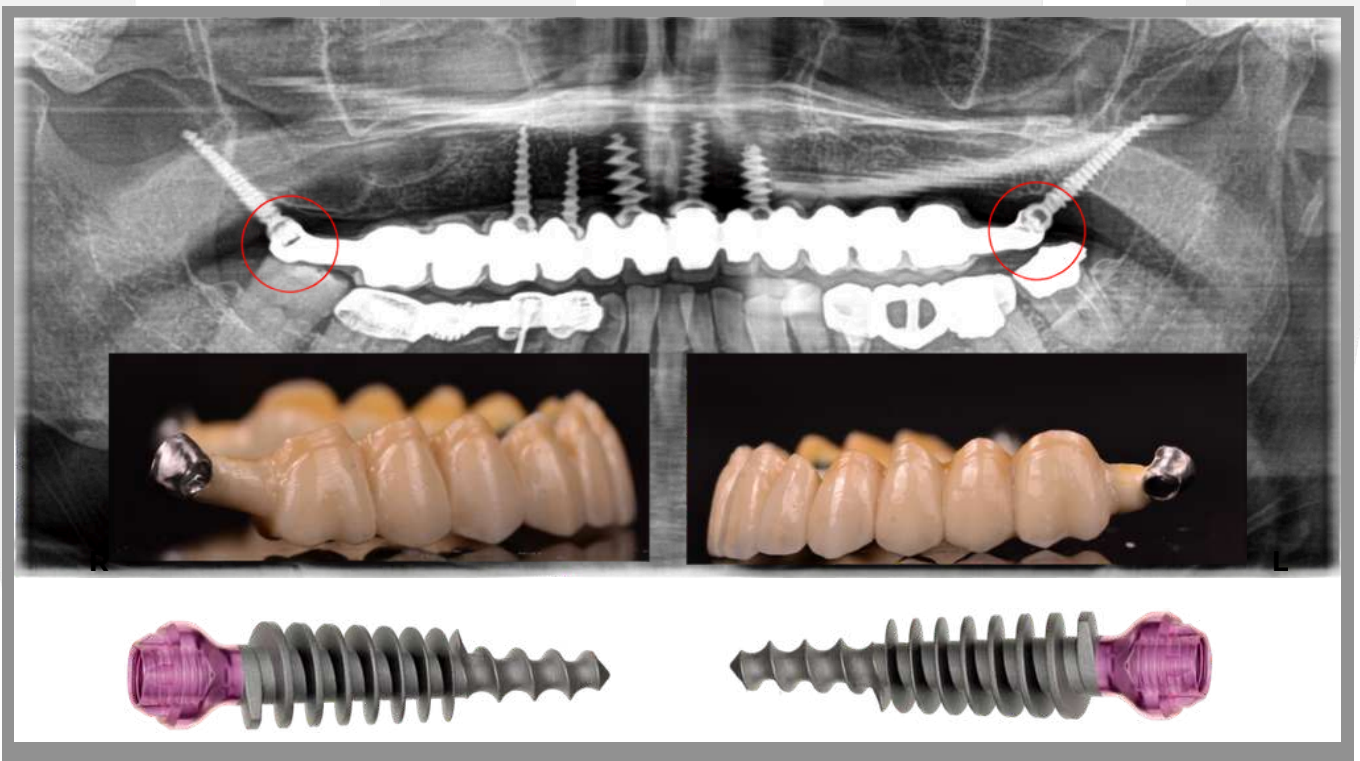
Patient Smile frontal view



Patient Smile full face view



Patient Smile Lateral view



Panoramic Xray for confirmation of prosthetic fit



## Clinical cases

# ROOTT M P

### Clinical situation

A male patient in his early 70s presented with an edentulous maxilla, severely compromised by horizontal bone resorption, thin ridges, and sinus pneumatization.

Gender: Male

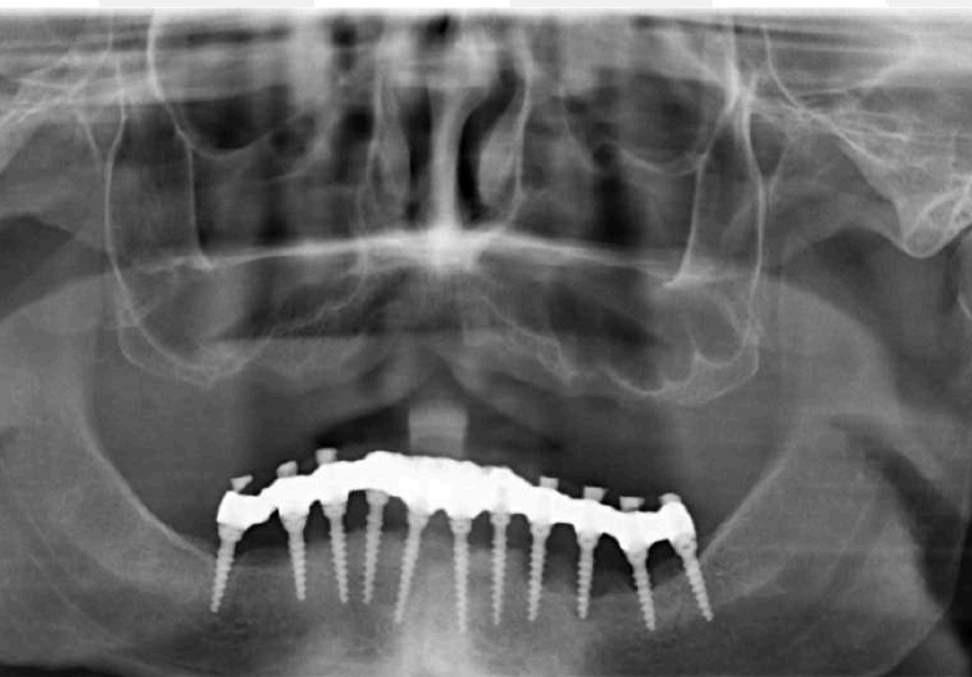Age: Early 70s

Graftless placement of ROOTT M implants was performed in the anterior and premolar regions, while bilateral ROOTT P (pterygoid) implants provided strong posterior anchorage, bypassing sinus limitations.

A rigid PFM Bone Truss Bridge (BTB) was designed following Dr. Henri's protocol to ensure optimal load distribution and biomechanical stability.

The final prosthesis was delivered successfully without complications.

This case demonstrates an effective graftless All-on-ROOTT approach, combining M and P implants with a BTB framework to achieve stable, functional full-arch rehabilitation in severely compromised bone.

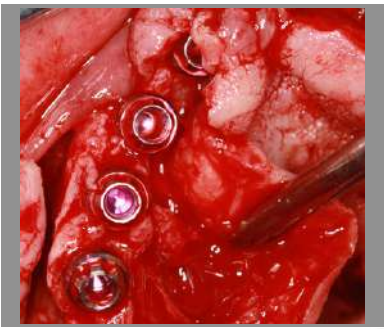


Preoperative panoramic Xray

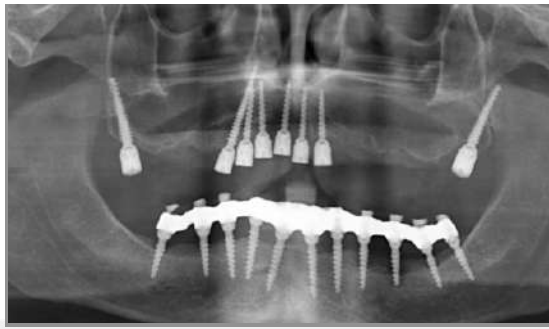

## Dr. Henri Diederich DMD

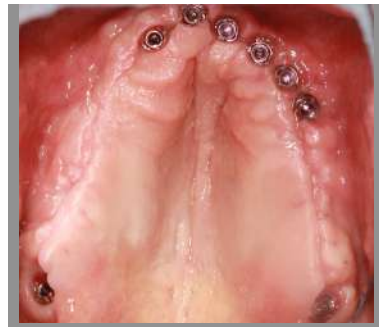- Implantologist & Oral Rehabilitation Specialist, Luxembourg
- 35+ years of clinical experience in advanced dentistry and implantology
- Pioneer in cortical implantology and immediate loading concepts
- Expert in full-arch rehabilitation and treatment of atrophied jaws
- Founder & President of Implantal Club Luxembourg
- President of Open Dental Community (ODC)
- International keynote speaker at global implantology congresses
- Lecturer in implantology programs across Europe and international universities
- Developer of patented implant concepts and minimal invasive treatment protocols
- Sworn dental expert in Luxembourg courts



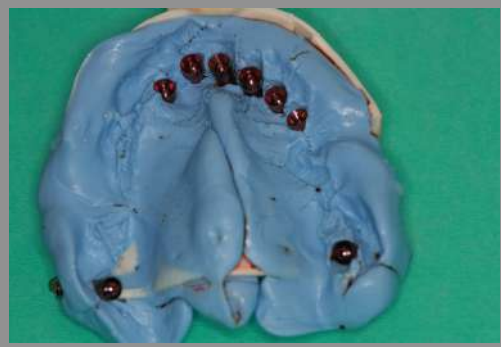Placement of implants



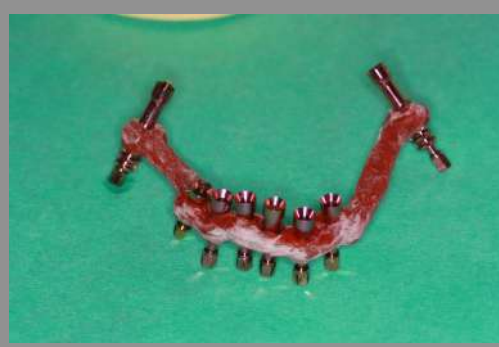Panoramic Xray with Implants placed in oremaxilla and pterygoid region



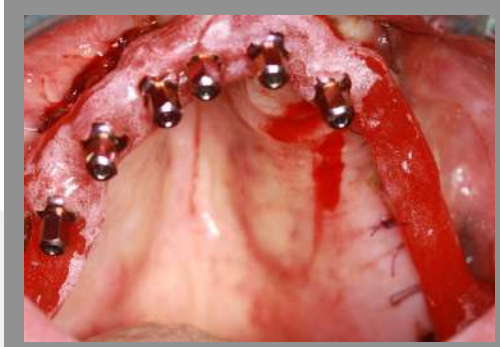Post operative intraoral healig after 10 days of surgery



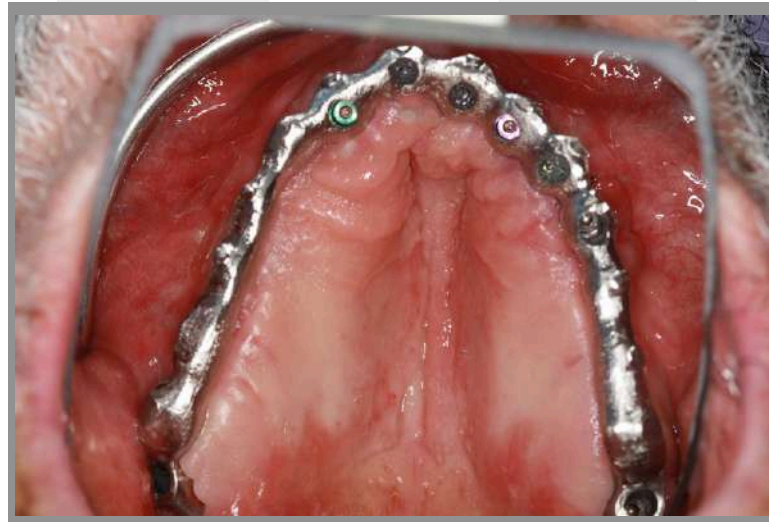
Impression open tray technique for prescise impression taking



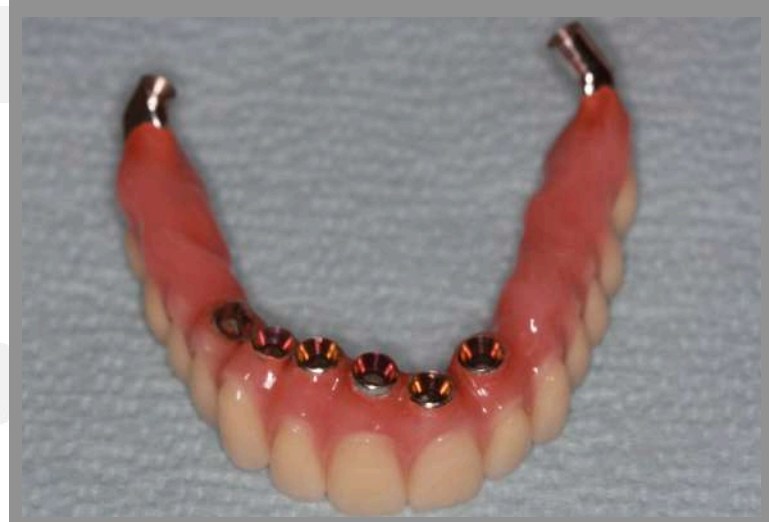Verification jig with impression coping on MUA



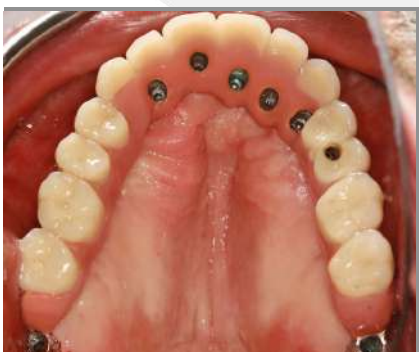Verification jig with impression coping on MUA intra oral



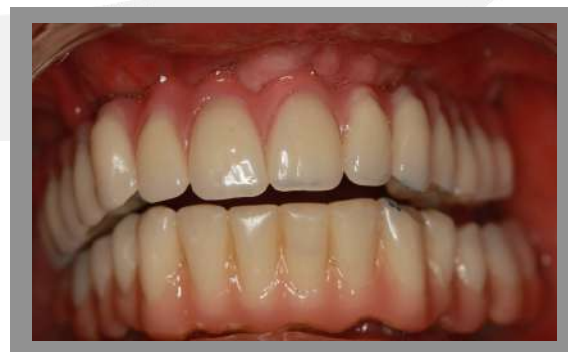Metal framework try-in



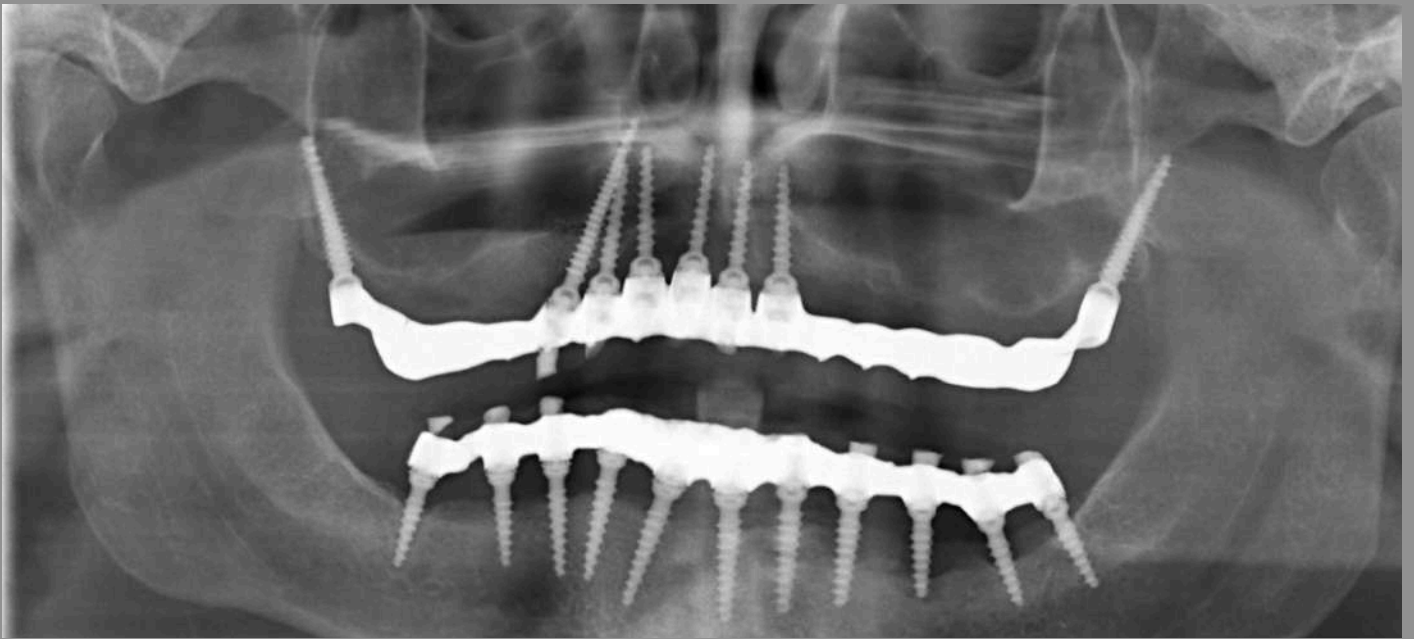
PFM prosthesis in lab



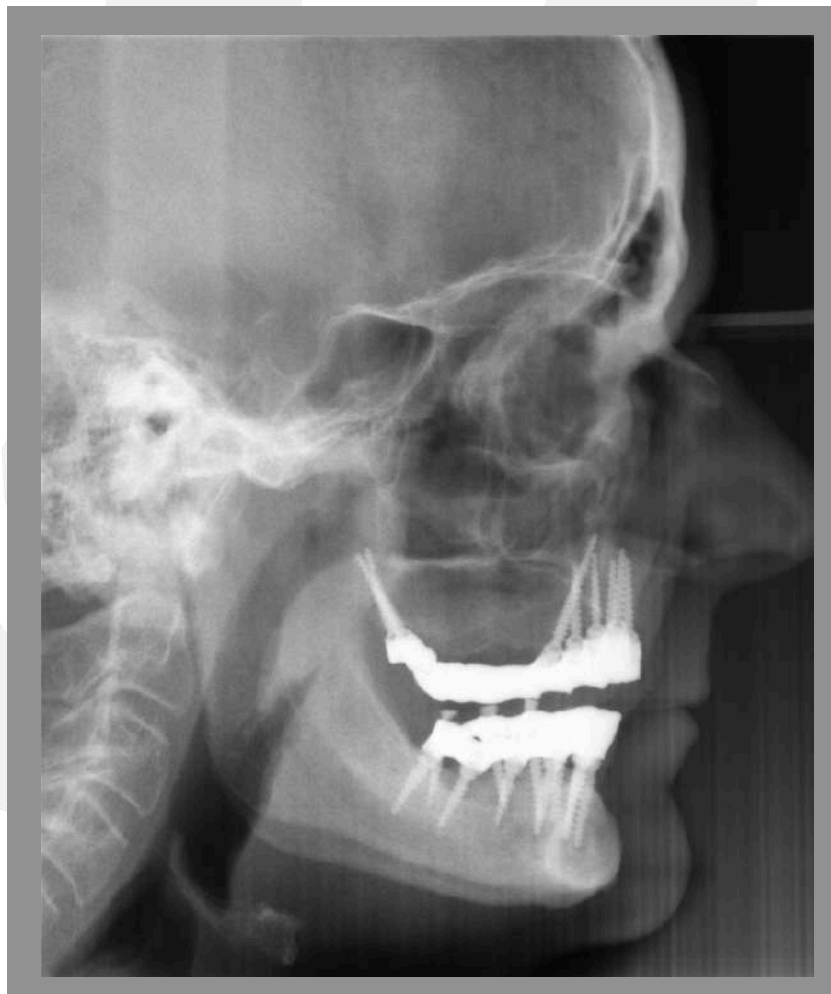PFM prosthesis in intra oral



PFM prosthesis in intra oral front view



Panoramic Xray with prosthesis seating and evaluation



Cephalometric Xray with prosthesis seating and evaluation



## Clinical cases

# ROOTT M P

### Clinical situation

A female patient in her early 50s presented with failing maxillary dentition and severe anatomical limitations, including sinus pneumatization, posterior bone loss, and thin alveolar ridges.

Gender: Female

Age: 65

All remaining teeth were removed, followed by placement of 4 ROOTT M implants in the anterior maxilla and bilateral ROOTT P (Pterygoid) implants in the posterior region to bypass sinus limitations and achieve stable anchorage.

This configuration provided a wide A-P spread with no distal cantilevers. ROOTT Multi-Unit Abutments were placed, and a screw-retained PFM bridge was delivered within an **Accelerated 3-week protocol**.

The procedure was completed successfully without complications.

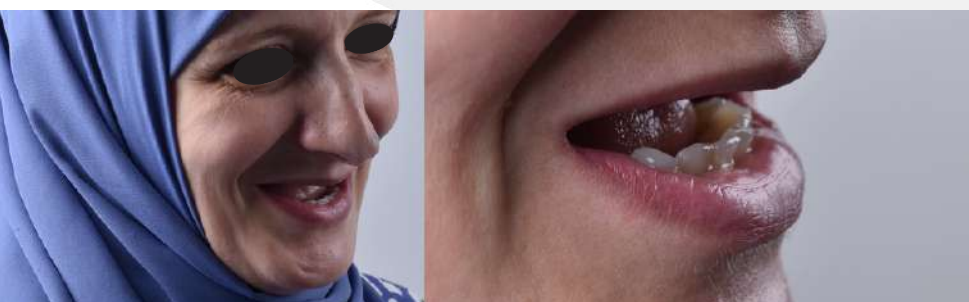

### Dr. Mohamed Babouche DMD

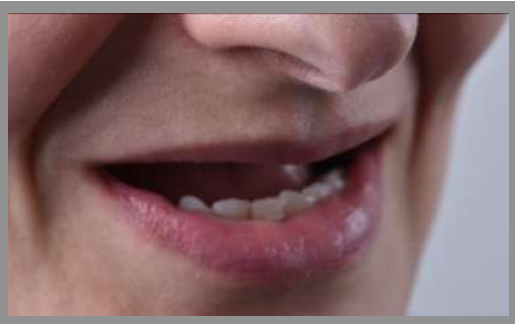- Implantologist & Dentist based in El Eulma, Sétif, Algeria
- Active clinician focused on implant dentistry and oral rehabilitation
- Specialist in immediate implantation, fixed restorations, and esthetic implant solutions
- Strong focus on practical implant workflows and patient-centered outcomes
- International trainer in implantology through Babouche Asnane Academy
- Conducts hands-on training programs and beginner-to-advanced implant courses
- Associated with ROOTT implant education and clinical training initiatives
- Fluent in Arabic and French, working across diverse patient profiles



Preoperative profile pictures of patient straight / lateral full face.



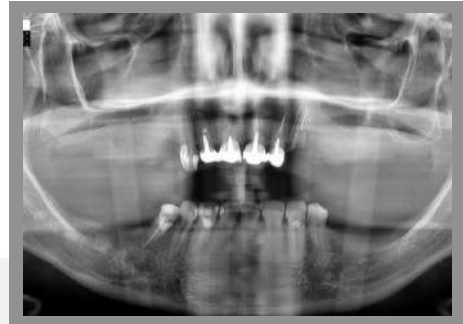
Preoperative profile pictures of patient oblique and close-up oral



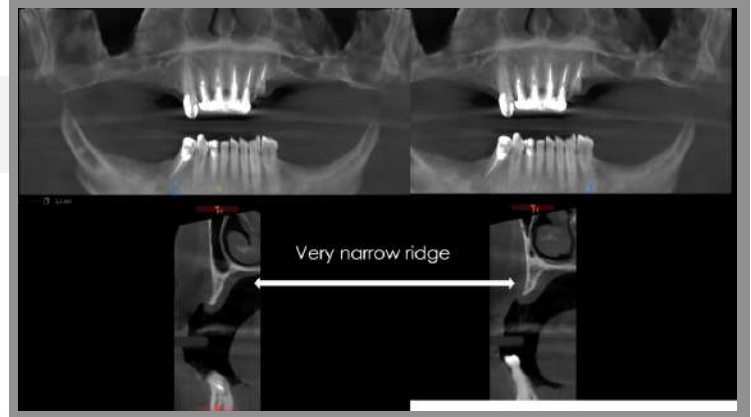
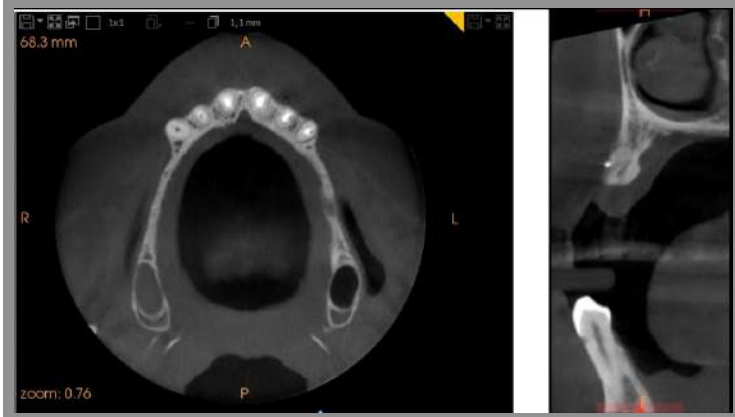
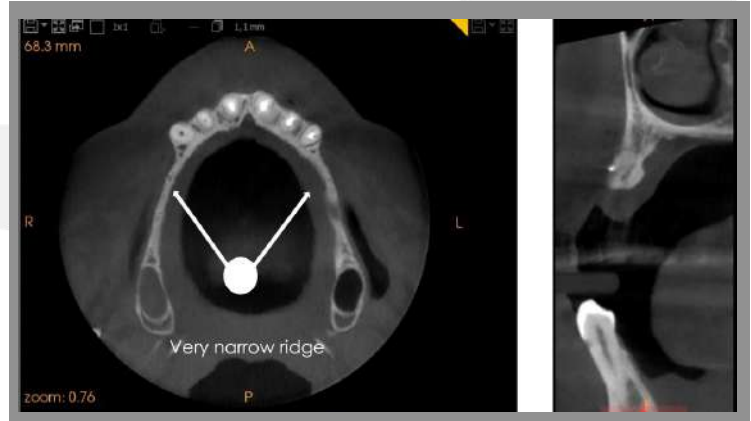
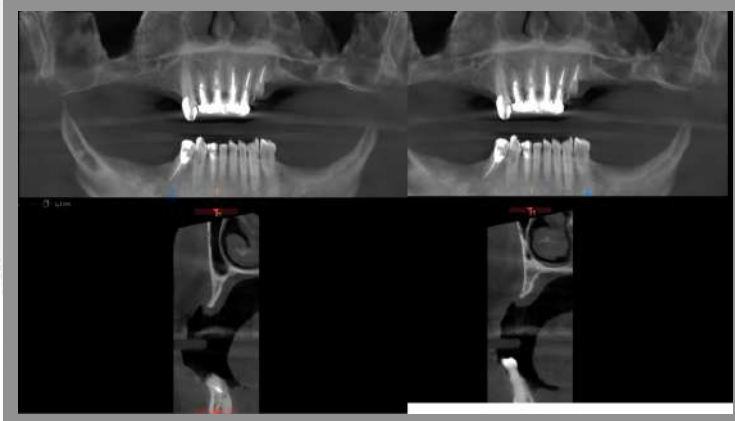
Preoperative intra-oral profile pictures



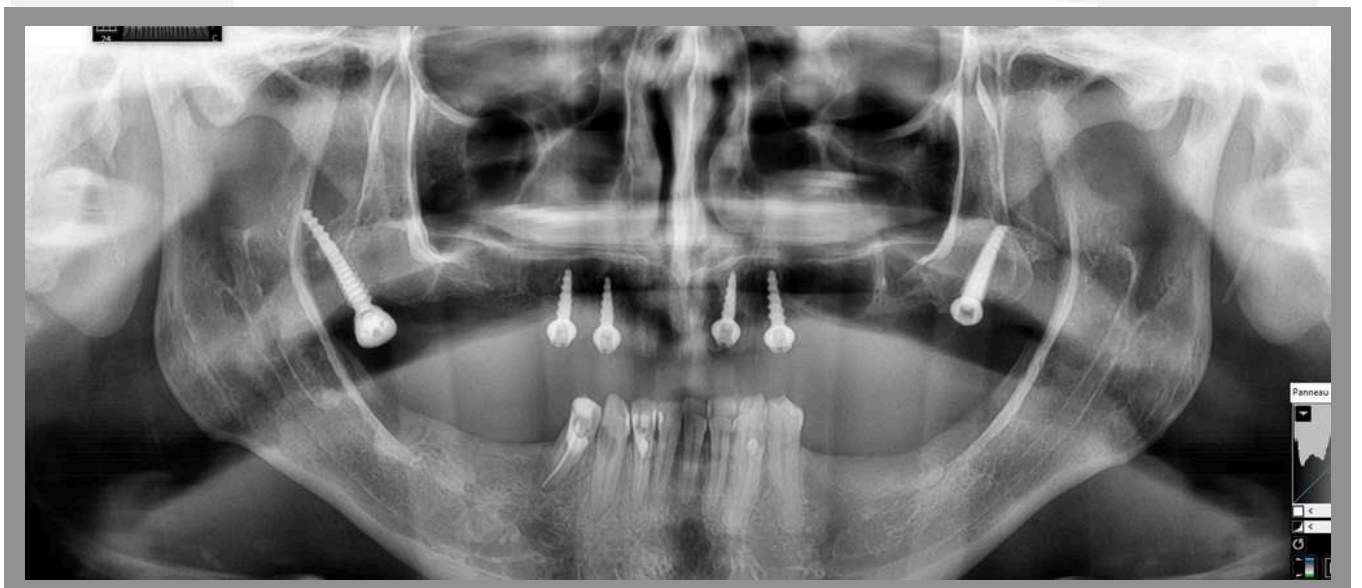Preoperative profile pictures of patient laughing



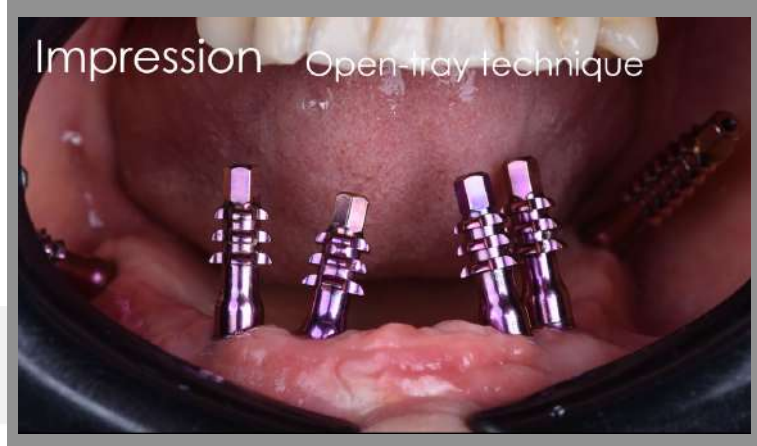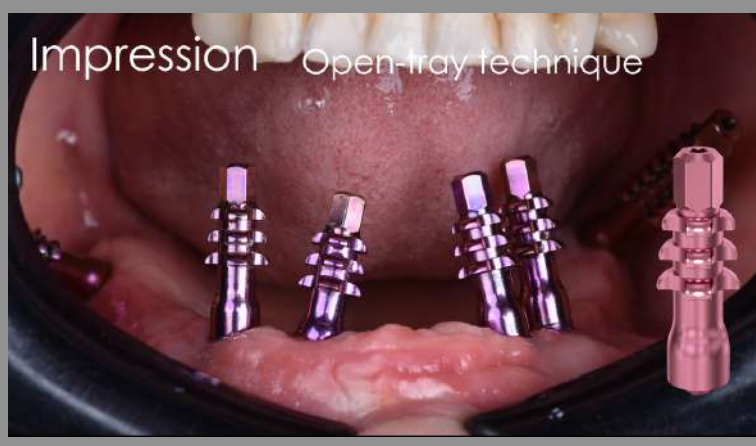
Preoperative panoramic view



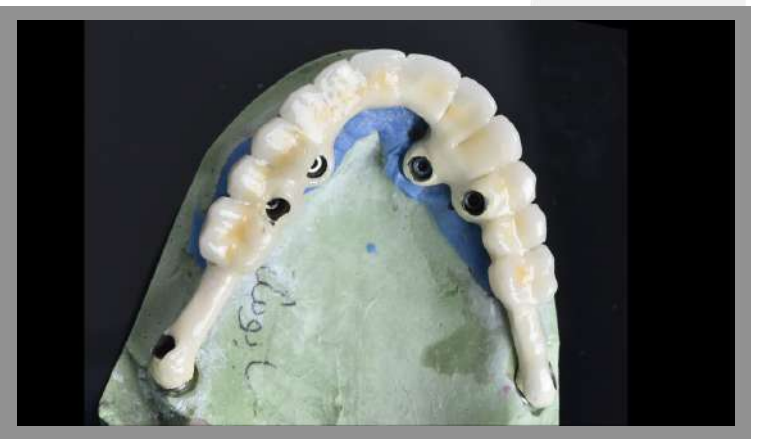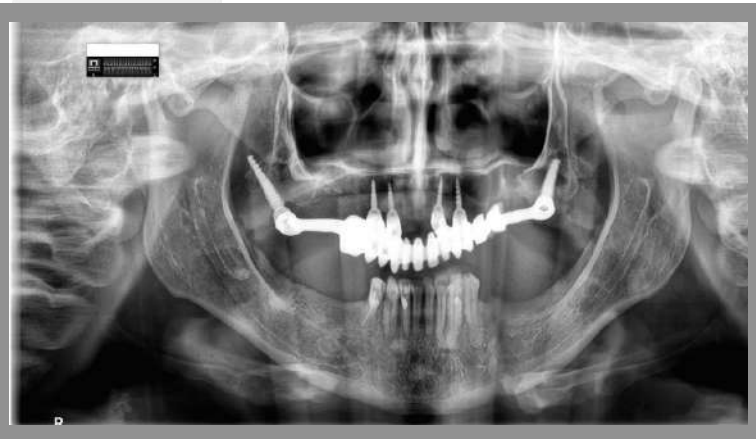
Preoperative CBCT view of the sinus and alveolar ridge



Post-operative Panoramic xray of the patient with ROOTT M and ROOTT P implants in a classic formation 4 anterior and 2 Pterygoids

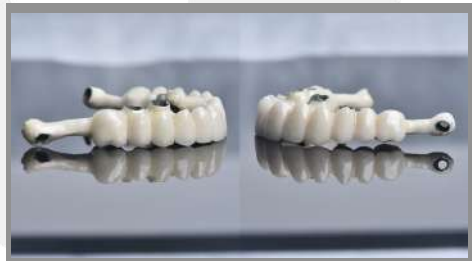
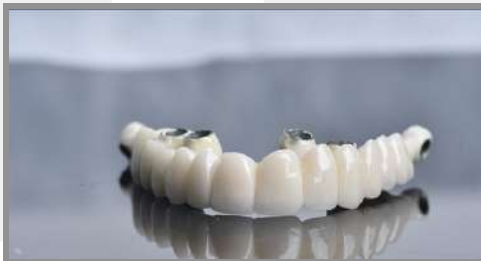
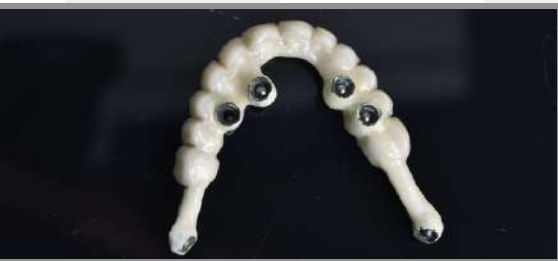Open tray impression posts for precise impression taking

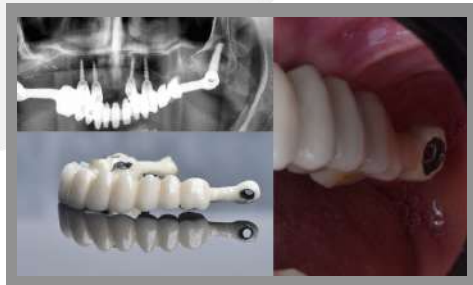
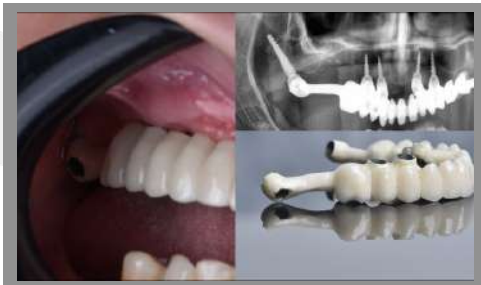
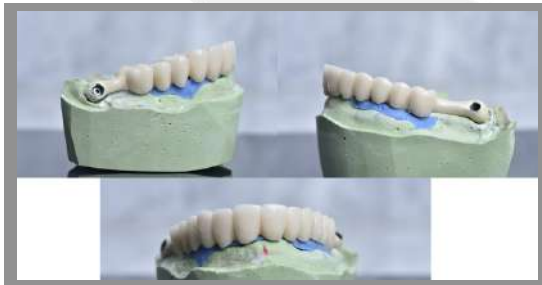Post-operative Panoramic xray of the patient with PFM Prosthesis

Prosthetic lab work on master cast of patient



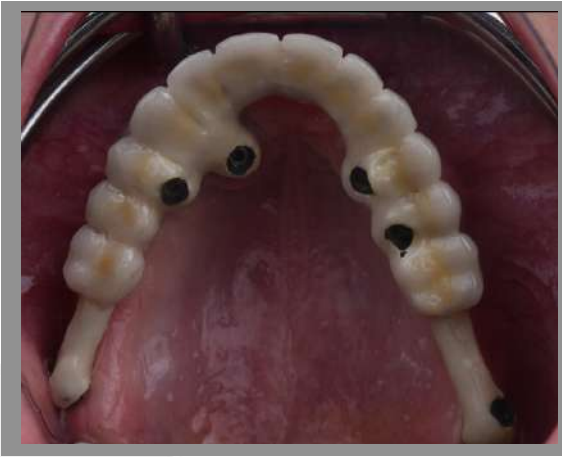PFM prosthesis tissue surface view



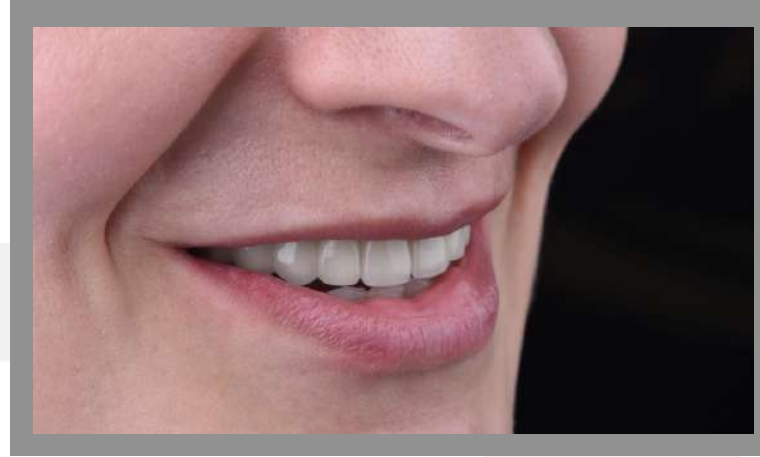PFM prosthesis lateral surface view on master cast

Prosthesis view left side with post operative panoramic Xray

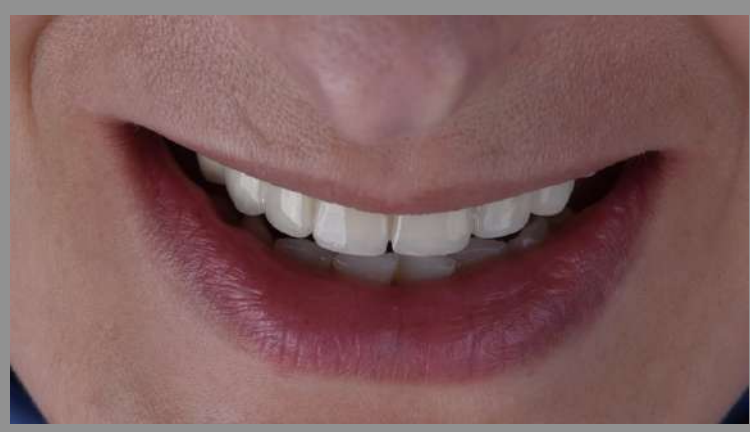Prosthesis view right side with post operative panoramic Xray



PFM prosthesis placed intra oral view of the patient



Smile profile of the patient postoperative - close up



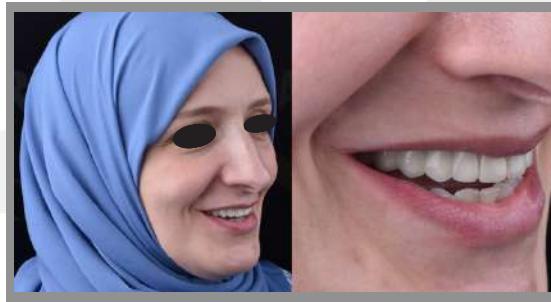Smile profile of the patient post operative close up with incisor view



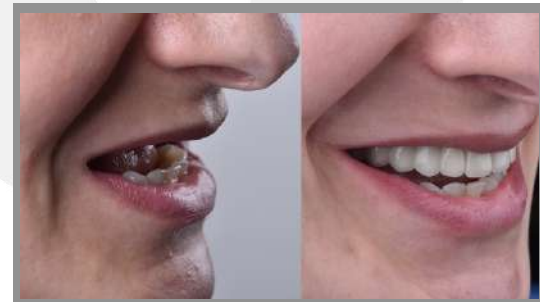Smile profile of the patient post operative front profile




Laughing profile of the patient post operative front profile



Laughing profile of the patient post operative lateral profile



Before and after patient profile close up



Before and after patient profile close up smile



Before and after patient profile close up laughing



## Clinical cases

# ROOTT **C**

### Clinical situation

A male patient, 75 years old, with no significant medical history presented seeking a fixed implant-supported rehabilitation.

Gender: Male

Age: 75

The existing vertical dimension was used as a reference for both implant placement and fabrication of the PMMA provisional restorations.

The treatment included placement of ROOTT C One Piece Implants using an immediate loading protocol to achieve stable functional and prosthetic rehabilitation.

PMMA provisional restorations were delivered within 24 hours after surgery, followed by acrylic and zirconia restorative phases during healing and follow-up.

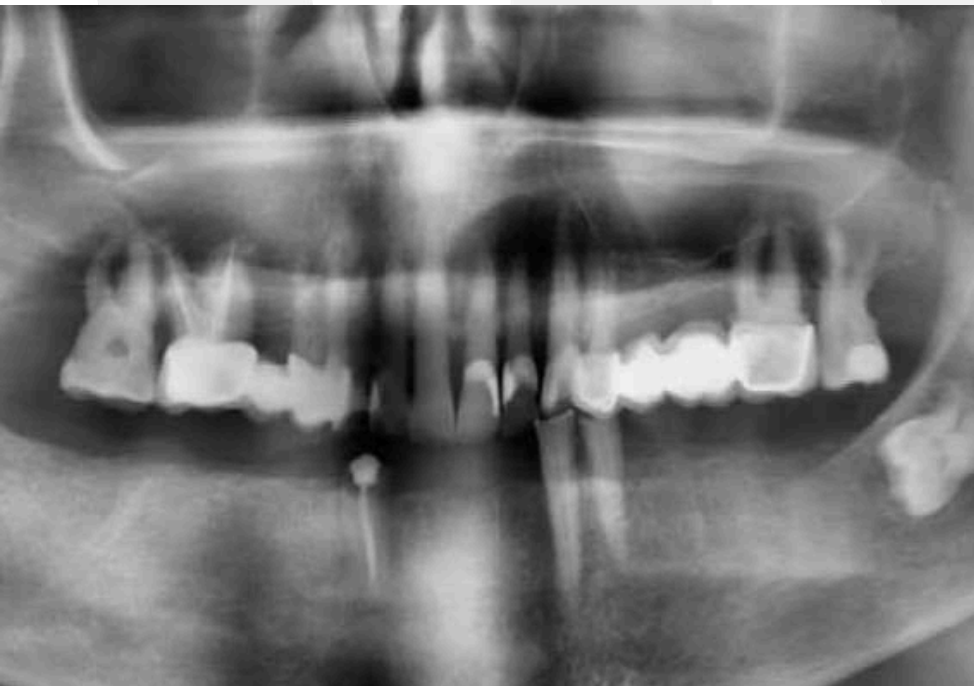The final ceramic restoration demonstrated stable implant integration and functional rehabilitation at the 3-year follow-up evaluation



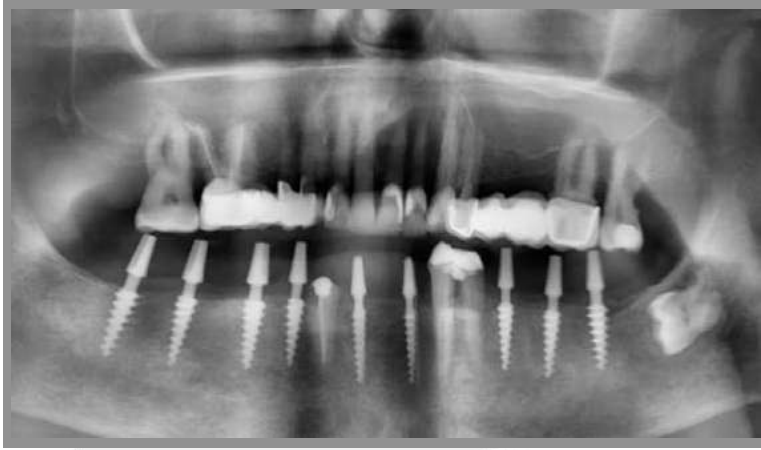## Dr. Fernando Mora Estévez

### DMD, PhD

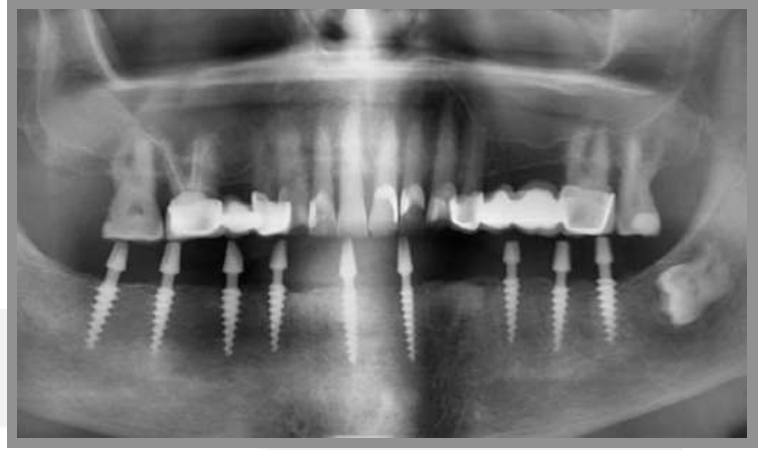- Specialist in implantology, periodontics, and esthetic dentistry
- Advanced expertise in guided surgery, immediate loading, and full-arch rehabilitation
- Strong focus on modern digital workflows and minimally invasive implant techniques
- Certified in All-on-4 rehabilitation and advanced implant surgical protocols
- Extensive training in bone surgery, aesthetic implantology, and oral rehabilitation
- Experienced in PMMA provisionalization and zirconia-based restorative solutions
- Active clinician associated with ROOTT España and advanced implant rehabilitation cases



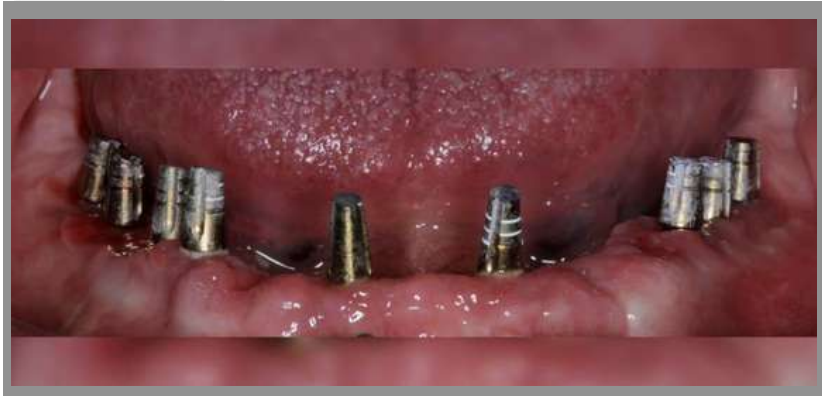Initial Radiograph



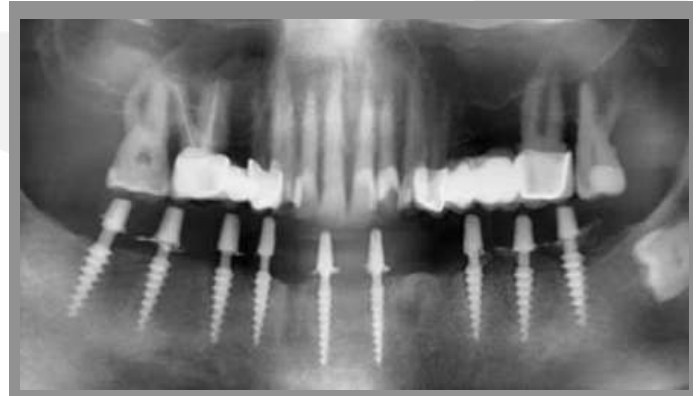
Intraoperative radiograph using the patient's teeth as a guide.



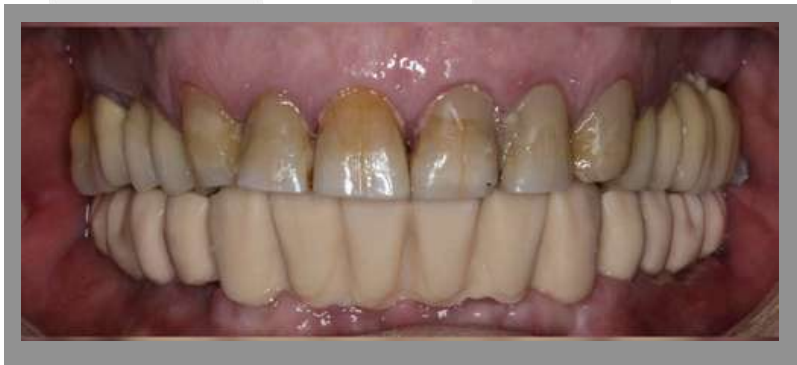Radiograph after abutment preparation for PMMA placement.



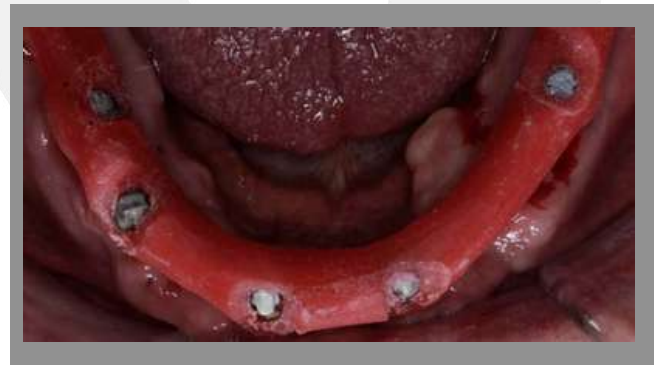Clinical situation at postsurgery.



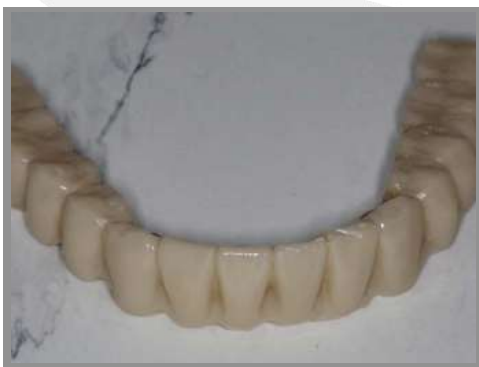Final radiograph after surgery with 24- hour preformed provisionals.



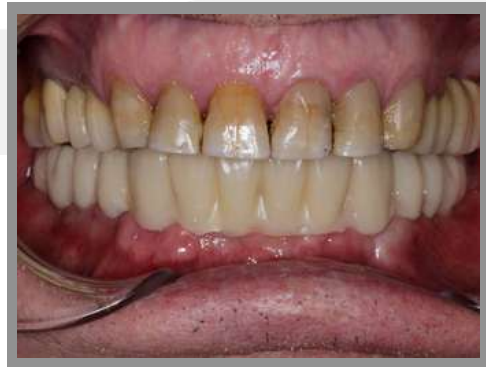Try-in of the resin prosthesis.



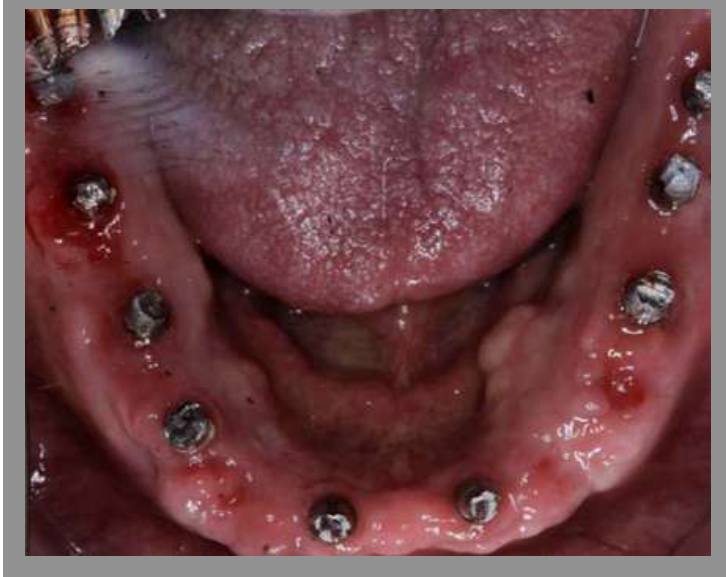Preparation index for PMMA in Duralay.



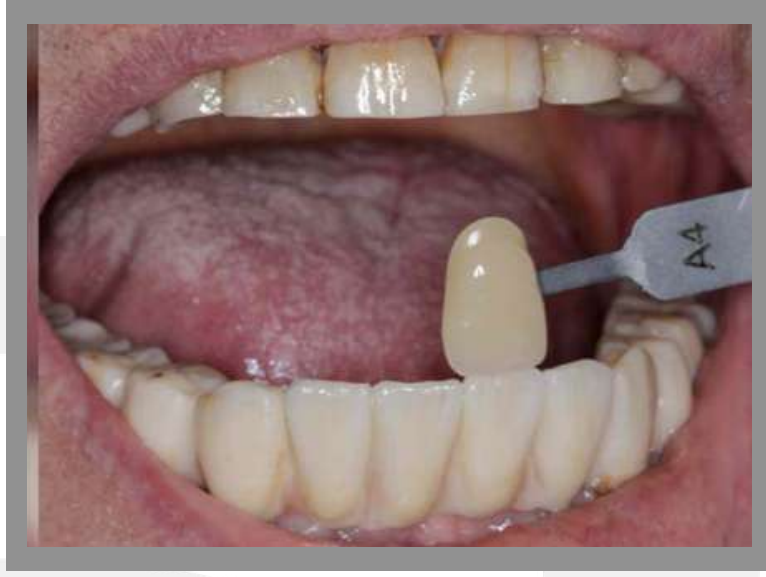PMMA provisional restorations.



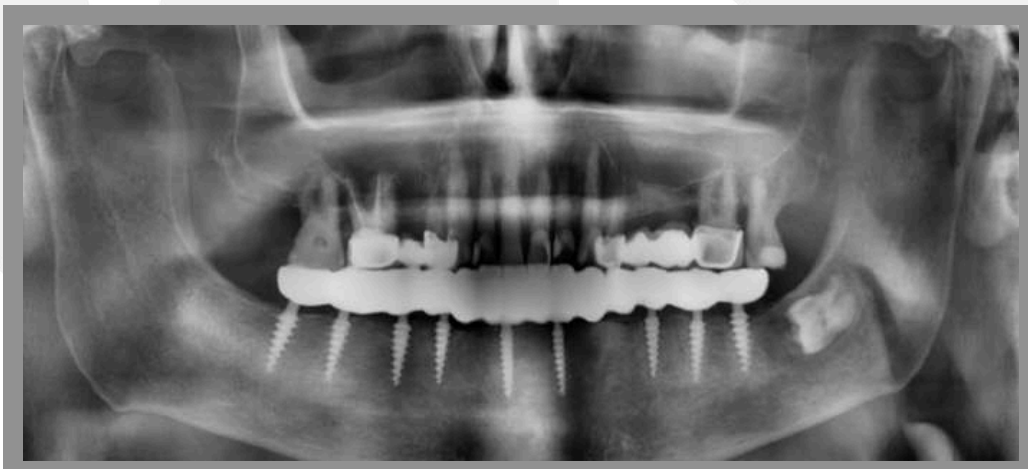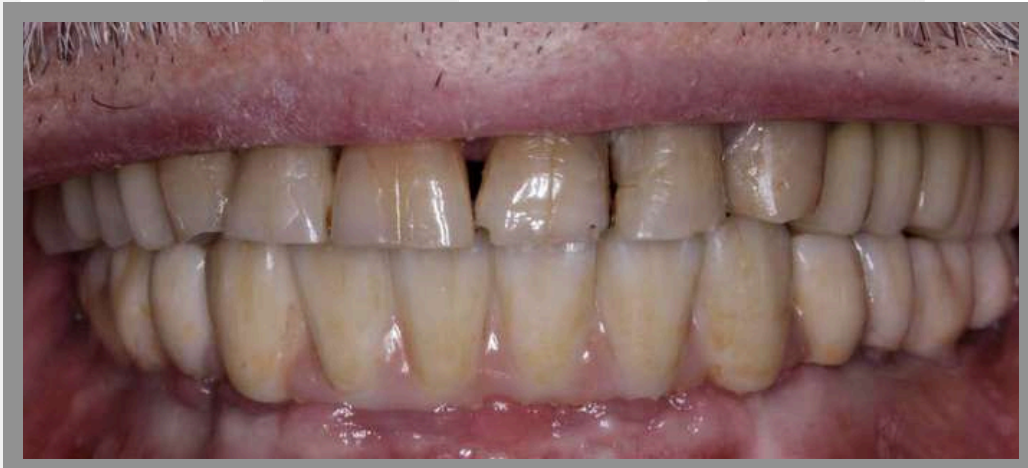PMMA provisional restorations.



Clinical situation at 3 months postsurgery.



Zirconia framework



Definitive ceramic Restoration and final radiograph 3 years Follow-up

# ROOTT

## Clinical situation

A female patient in her early 50s presented with a failing full-arch maxillary implant restoration, severely compromised by horizontal bone resorption and extremely thin alveolar ridges.

Gender: female

Age: early 50s

Failing implants were removed, followed by graftless placement of ROOTT C one-piece implants in thin bone. Immediate rigid splinting via intraoral welding ensured high stability.

A same-day provisional prosthesis was delivered, with final restoration completed using screwless, cementless ROOTT conometric caps.

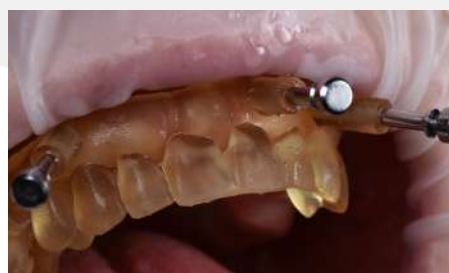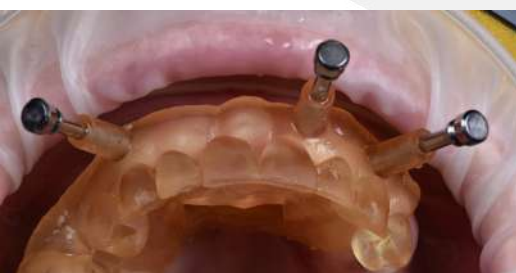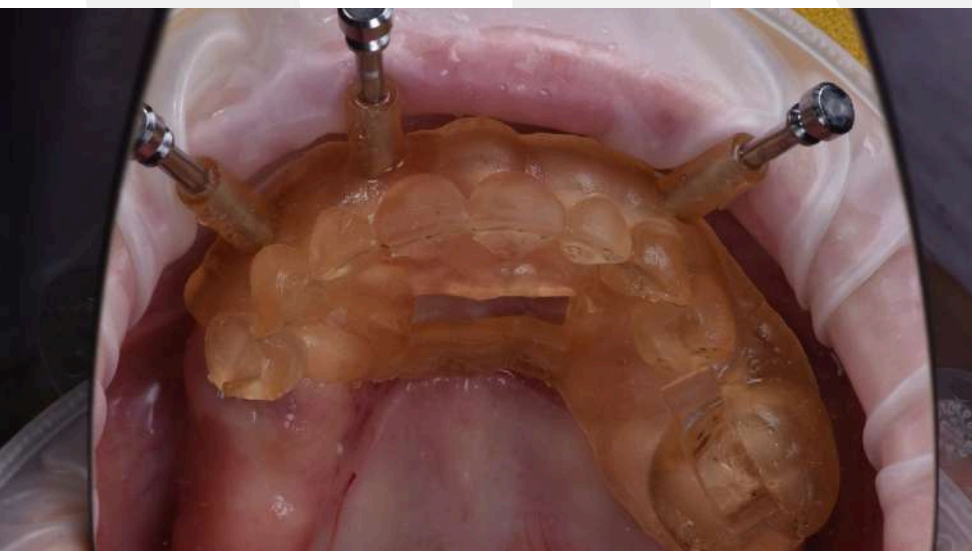The procedure was completed without complications, demonstrating a stable graftless solution for narrow ridges.



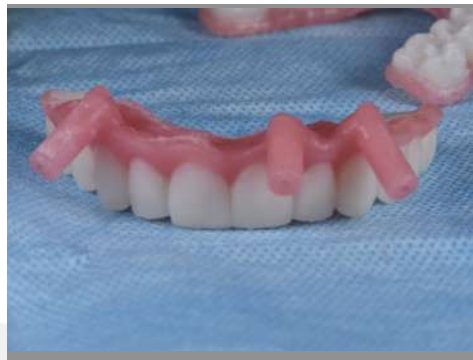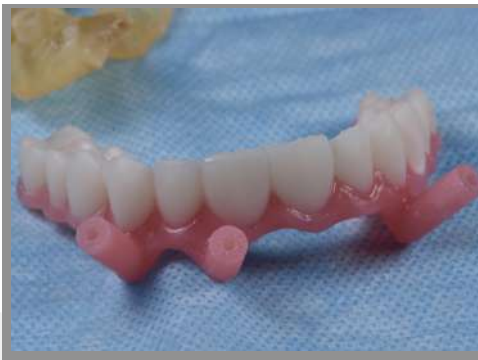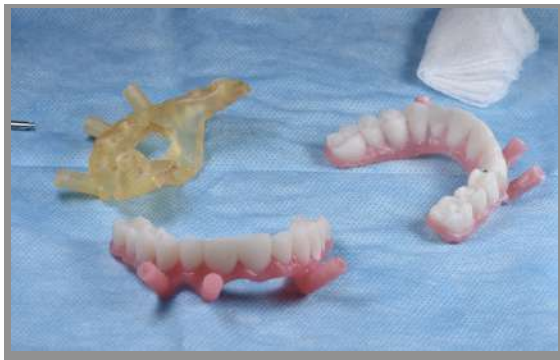## Dr. Adam Nowicki DMD, PhD

- A premier Polish expert in Digital Implantology and Prosthetic Reconstruction, based in Lubin and Wrocław.
- Developer of the Croco Eye Technique (CET)—a surgical method for the simultaneous removal of sinus cysts and sinus floor elevation.
- Assistant Professor at the Pomeranian Medical University (Szczecin), specializing in the biomechanics of the masticatory system.
- Known for bridging Clinical Dentistry with Mechanical Engineering, specifically in the 3D printing of dental resins and intraoral welding.

An international lecturer (ITI, Straumann) recognized for his expertise in Full-Arch Immediate Restorations using digital workflows.



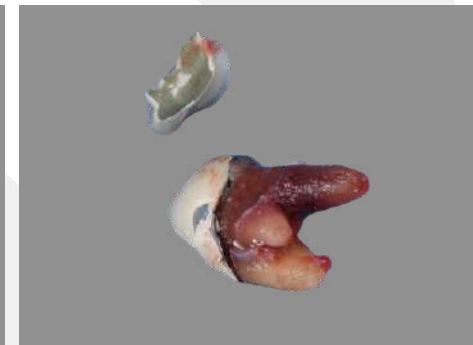
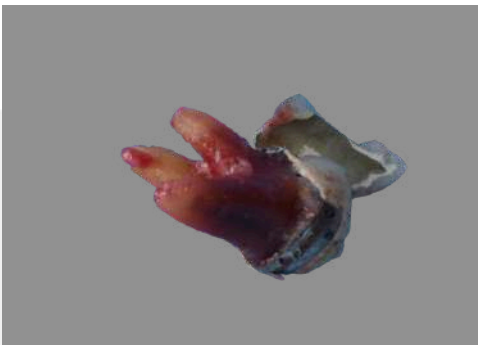
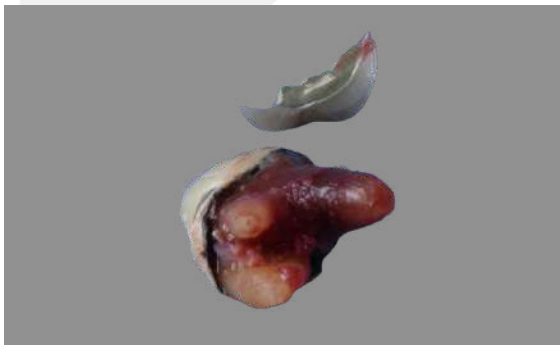Surgical Guide in place with remining teeth for orientation of Guide Pins



Guided Armanentarium , Surgical guide , Bite Prototype to establish occlusion , 3D Printed provisional

Bite Prototype for assesment of vertical Deimension

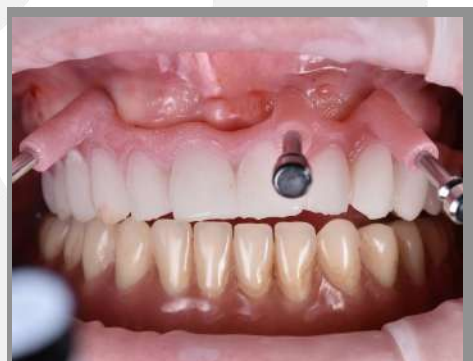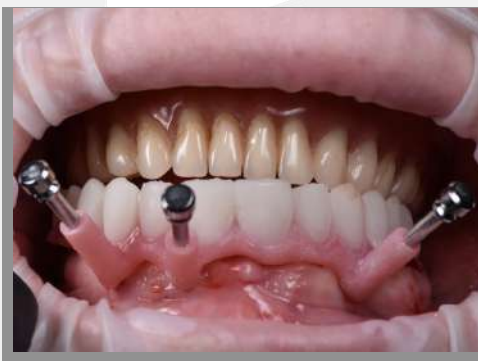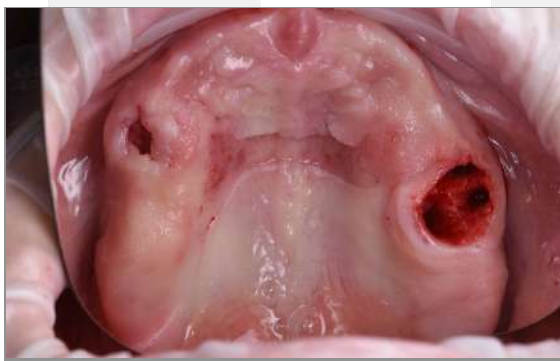3D printed provisional for immedate loading



Extracted molar left

Extracted molar right

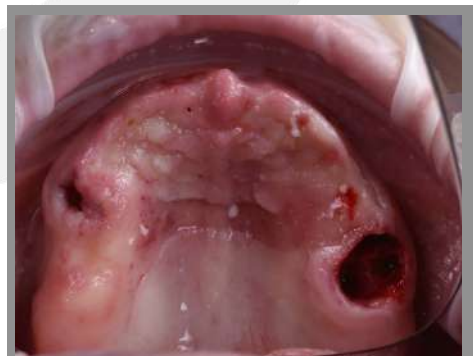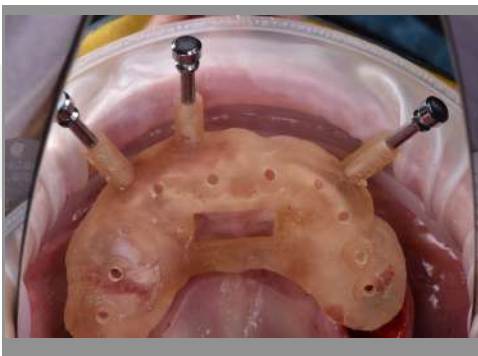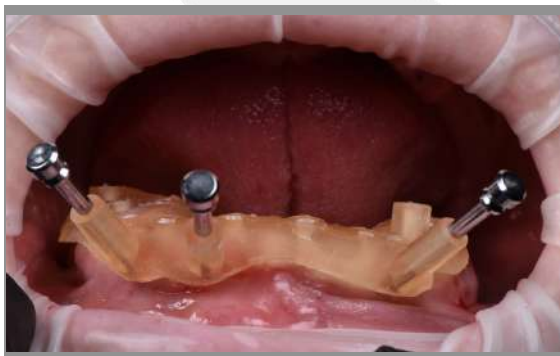Extracted molar left



Freshly extracted Full Arch Maxillary view

Bite Prototype in patients mouth for assesment of vertical Dimension and occlusal check

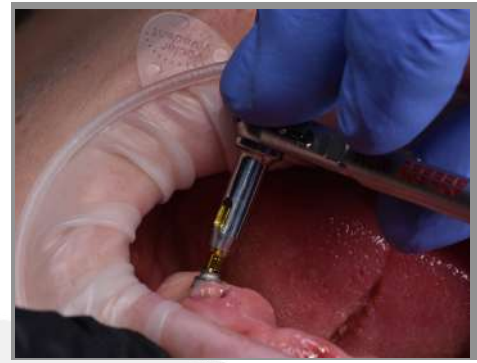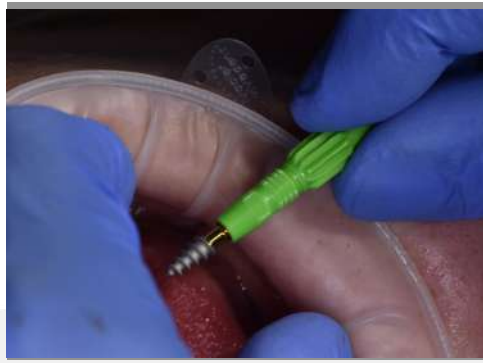Bite Prototype in patients mouth for assesment of vertical Dimension and occlusal check



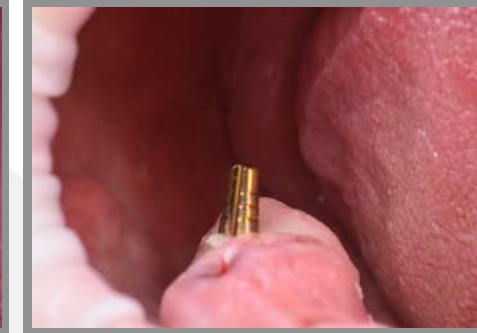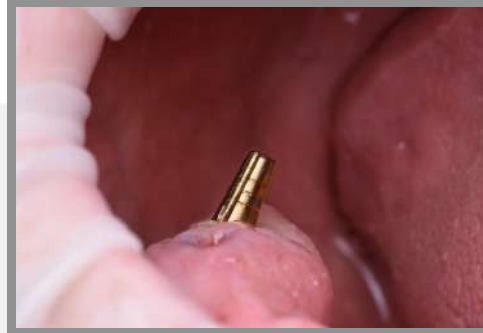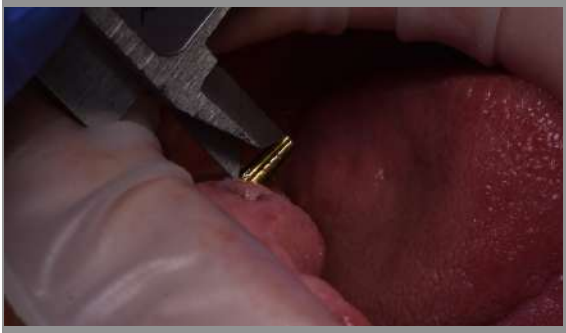Surgical Guide in place with the anchor pins

Surgical Guide in place with the anchor pins occlusal view

Minimal invasive drilling without flap elevation & minimal bleeding



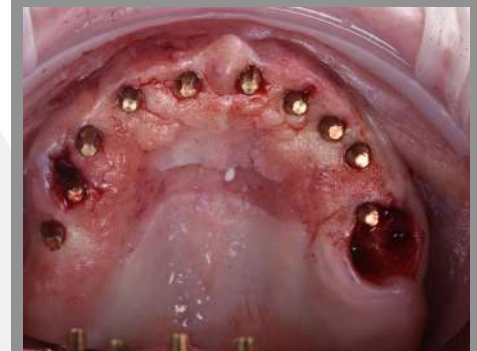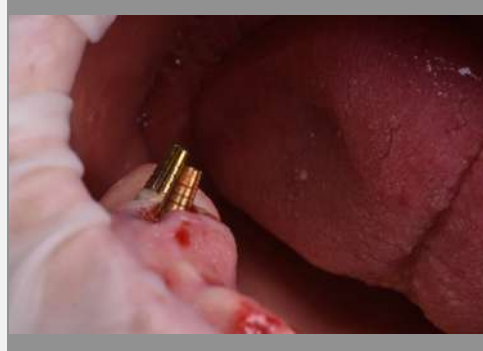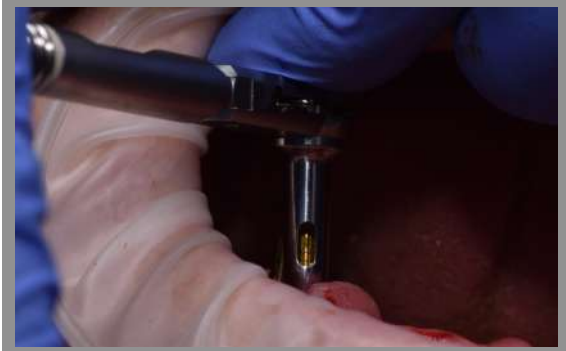ROOT C Implants in Action



Caliper to measure the abutment height

Implant in place

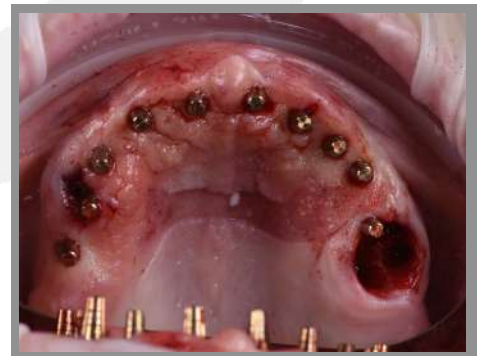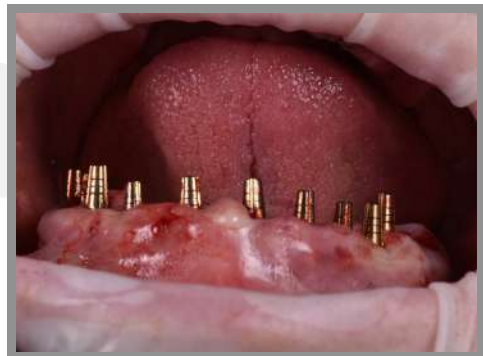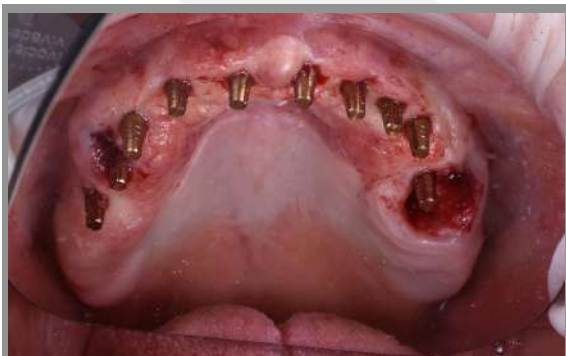Adjusted new height according to the Occlusal plane



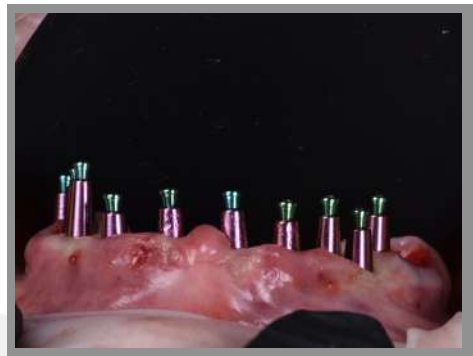
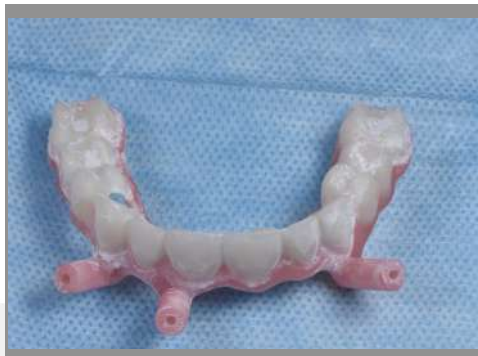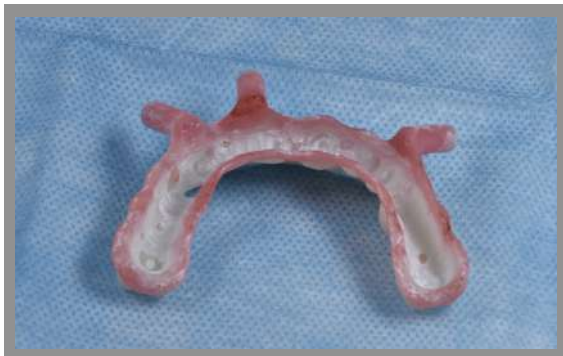New implant insertion

Implants placed at the same abutment height

All Implants placed Occlusal view



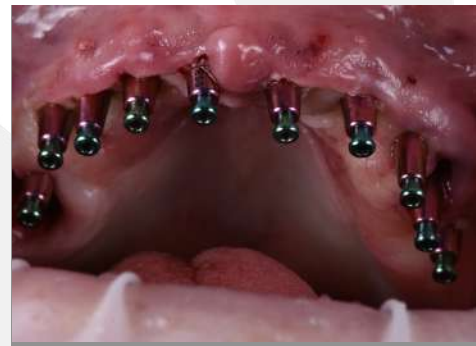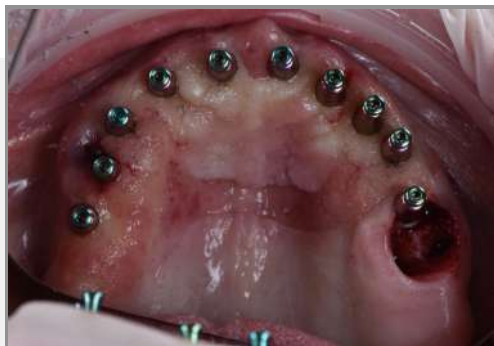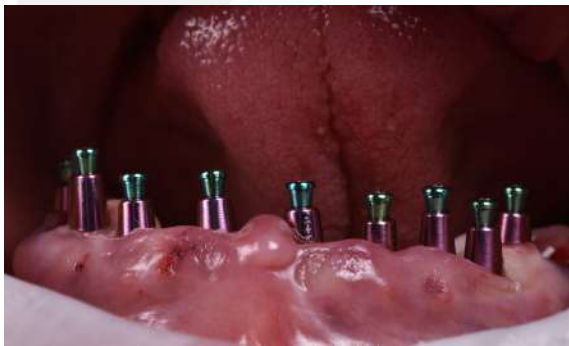All Implants placed Occlusal view



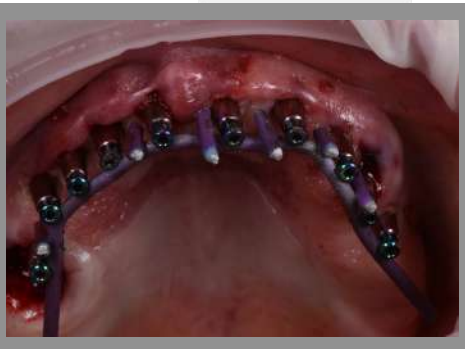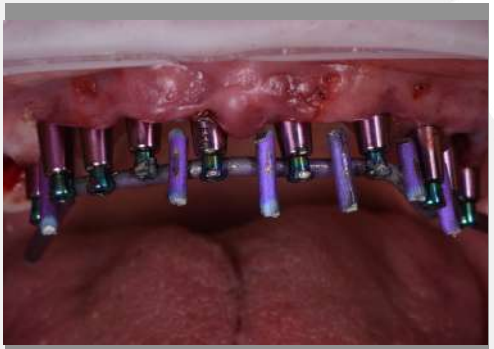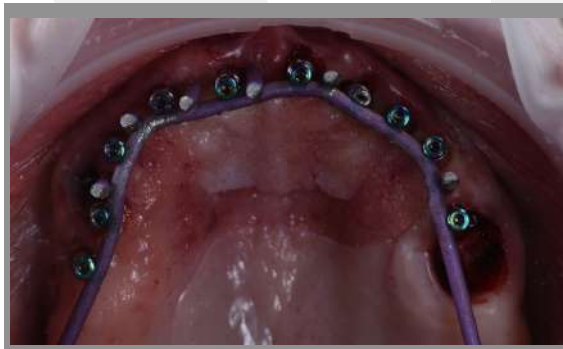3D printed provisional for immediate loading with Access points with corresponding implant positions Tissue view

3D printed provisional for immediate loading with Access points with corresponding implant positions

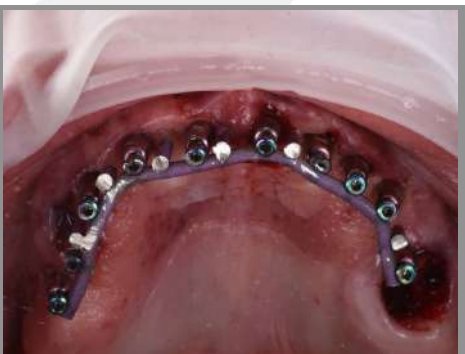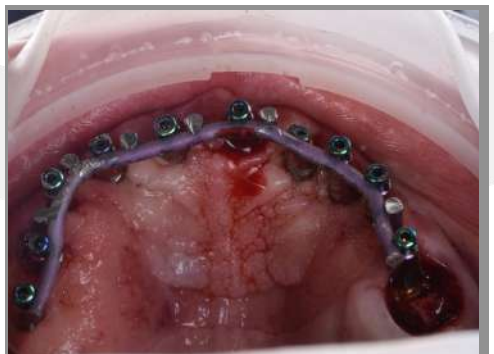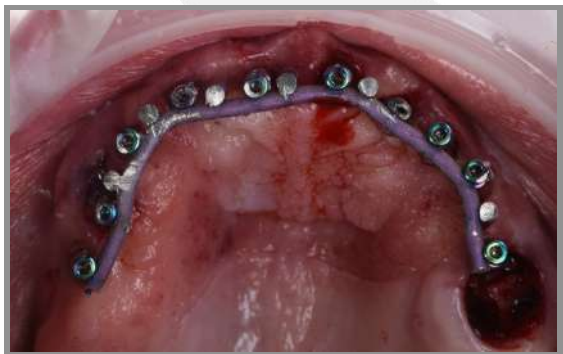Conometric caps in place with cover screw to assist in intra-oral welding



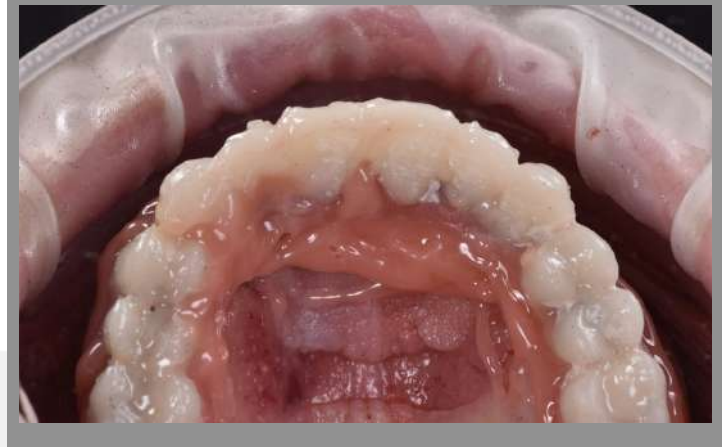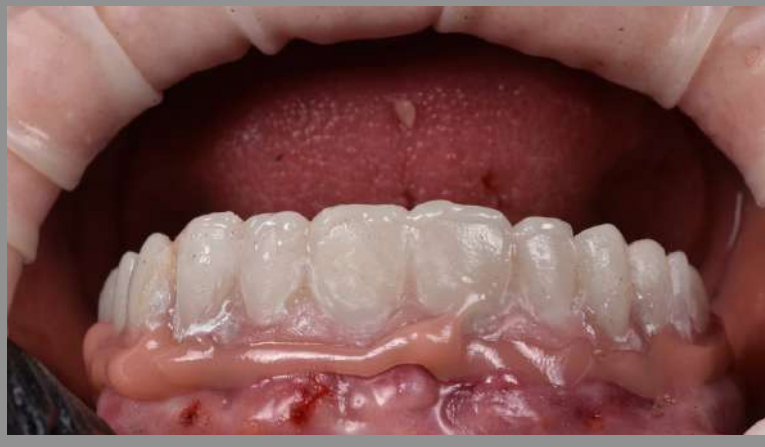Conometric caps in place with cover screw to assist in intra-oral welding



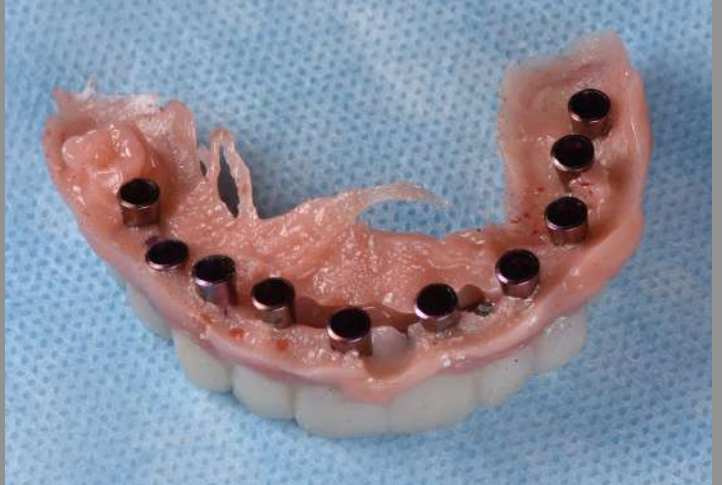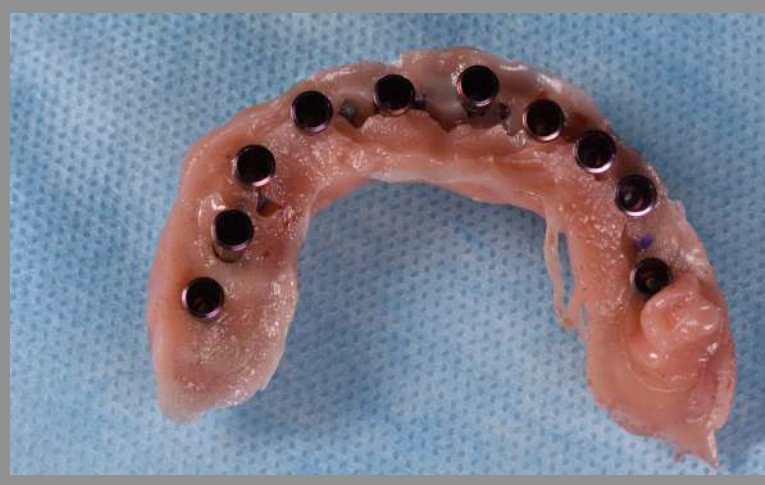Intra oral welding structure welded over the cover screw support



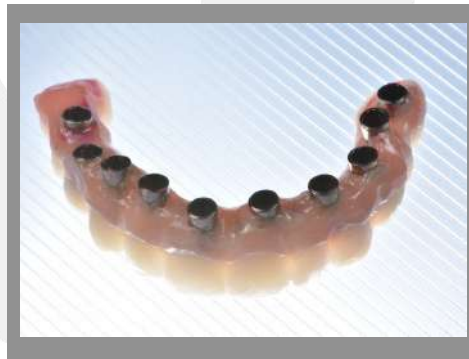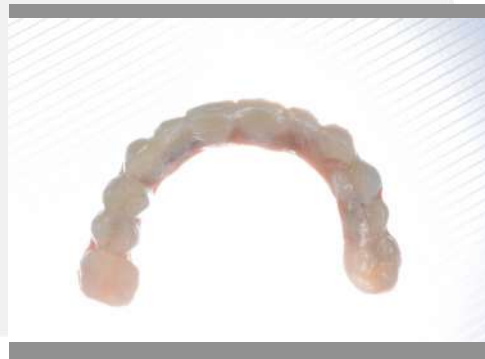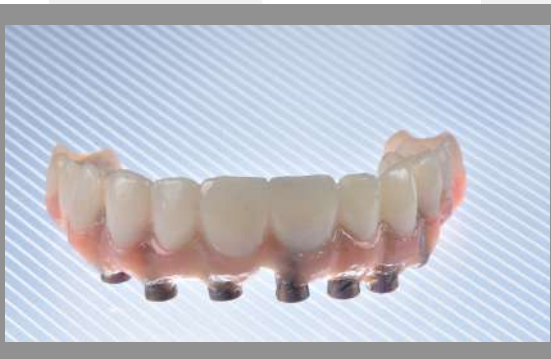Intra oral welding structure welded over the cover screw support Adjusted according to the arch



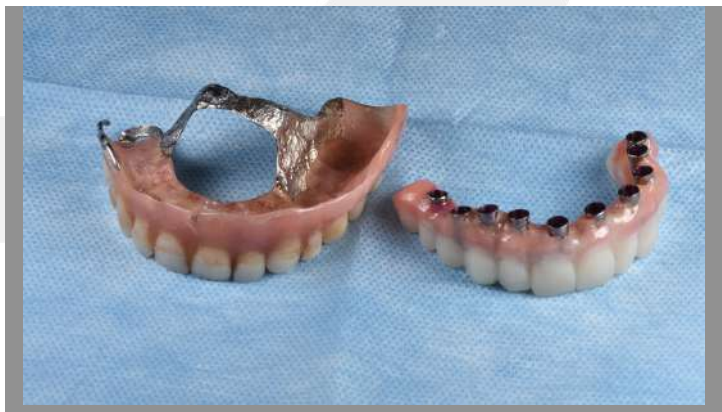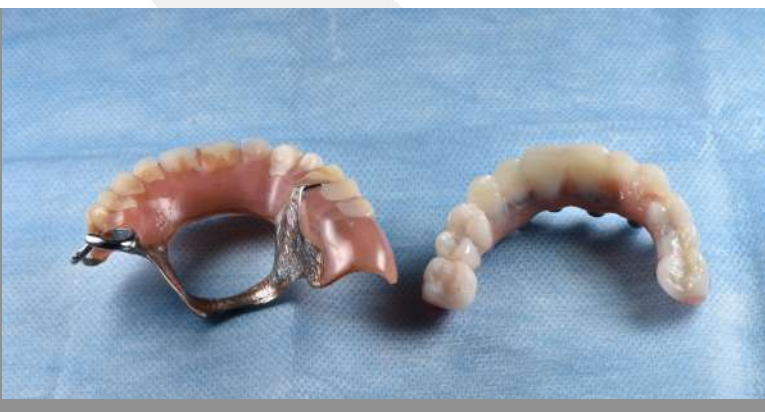Provisional Pick-up taken with pink resin inside the patient's mouth



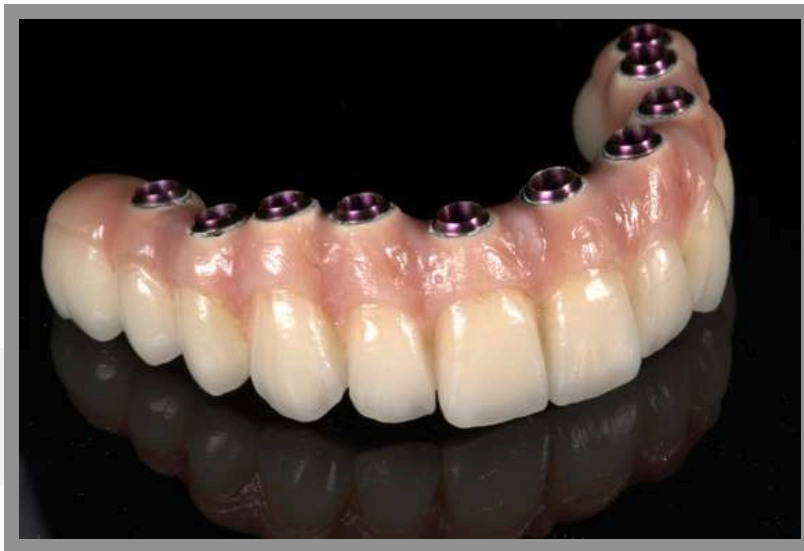
3 D Provisional outside with access



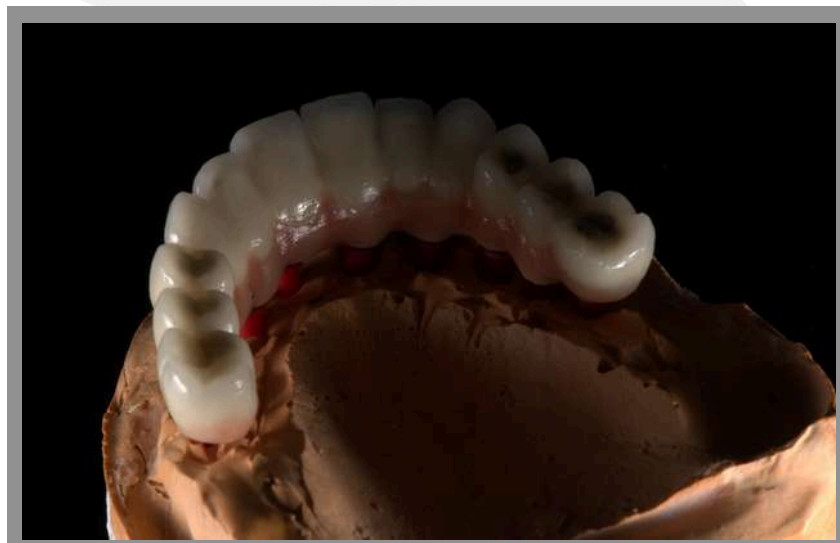
3 D Provisional outside adjusted for final seating



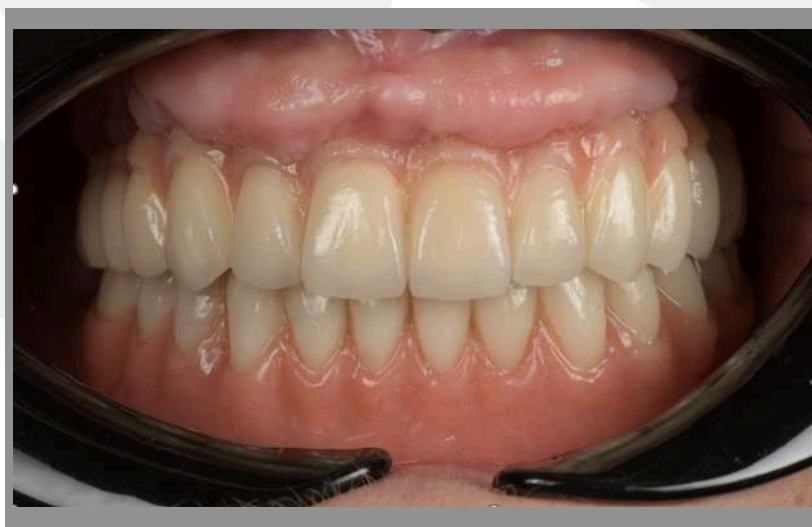Esthetic and functional difference between RPD & New Prosthesis



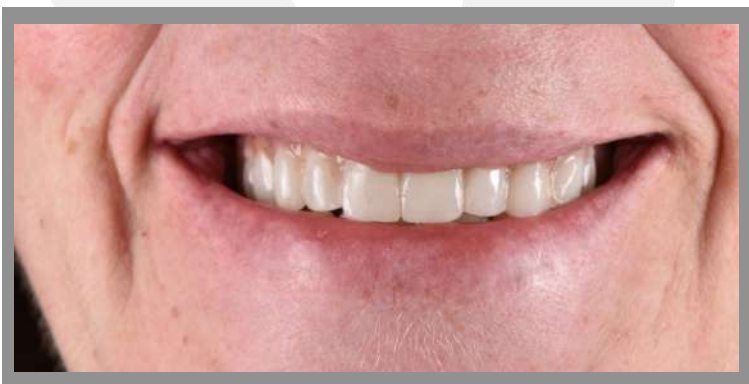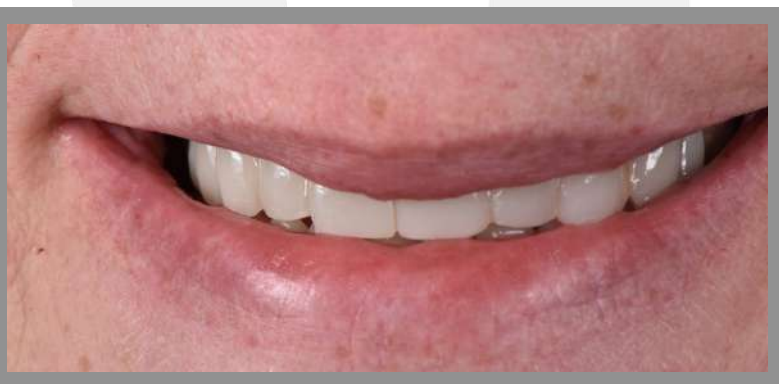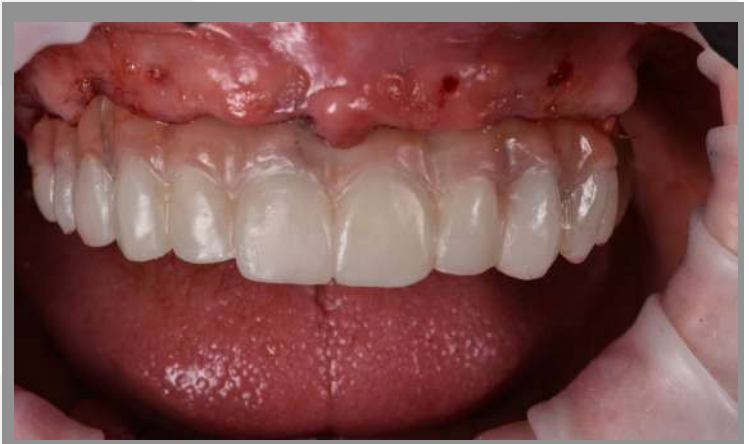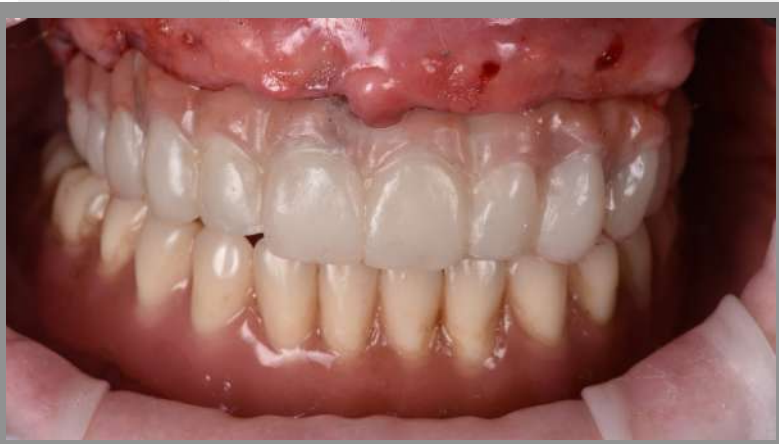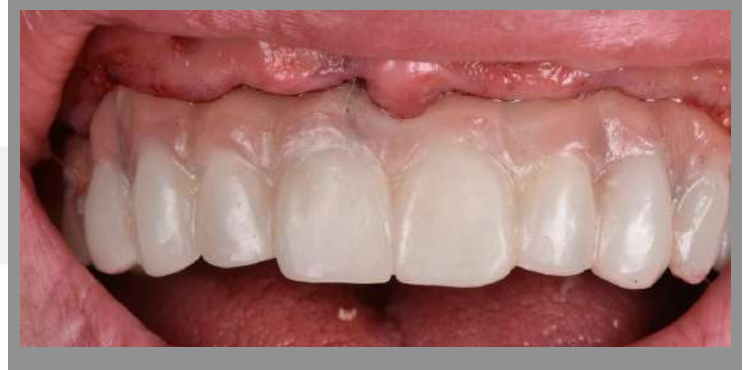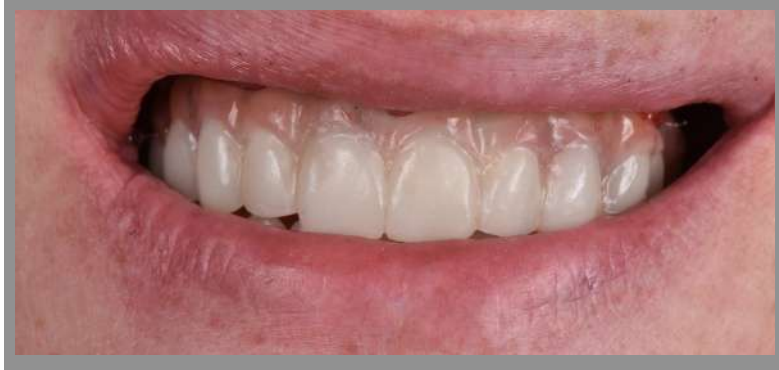Final prosthesis  
Full zirconia on conometric caps



Prosthesis in master cast



Prosthesis in patient



Esthetic inside the patients mouth



# Clinical cases

## ROOTT C BS

### Clinical situation

A 57-year-old patient presented with an edentulous upper jaw and a pre-edentulous lower jaw. He reported significant difficulty eating and general discomfort due to the use of removable dentures.

Gender: Male

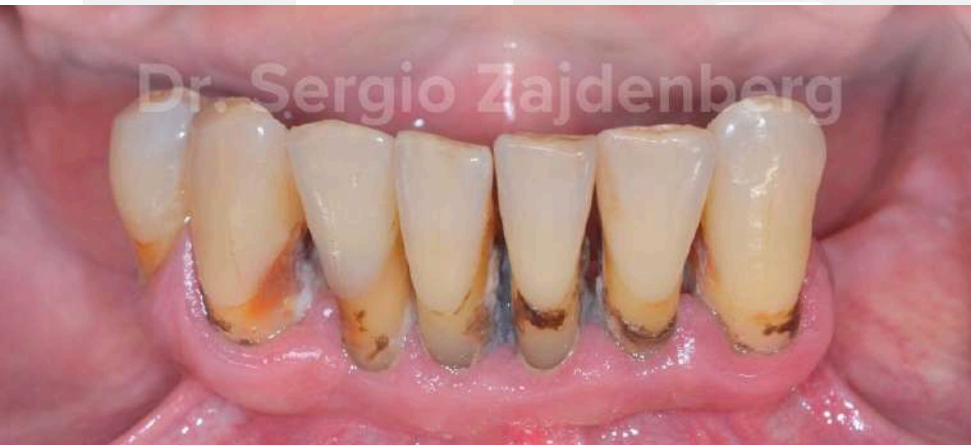Age: 57

Treatment involved the installation and immediate loading of multiple monoblock implants (compressive Roott C and basal Roott BS). Of the 18 implants placed, one in the mandible at the position of tooth 41 failed after 3.5 months. The final rehabilitation consisted of full-arch porcelain-fused-to-metal restorations for both the upper and lower arches. The entire treatment process lasted five months, and the use of a myorelaxant splint was prescribed to protect the restoration, particularly at night.

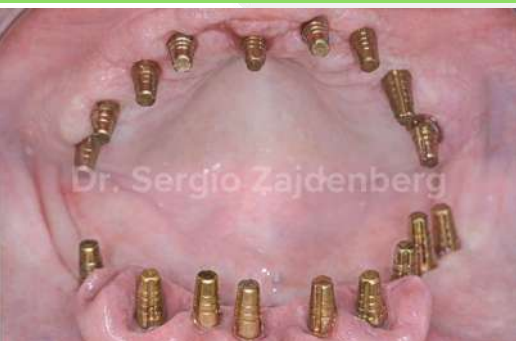

## Dr. Sergio Zajdenberg DMD

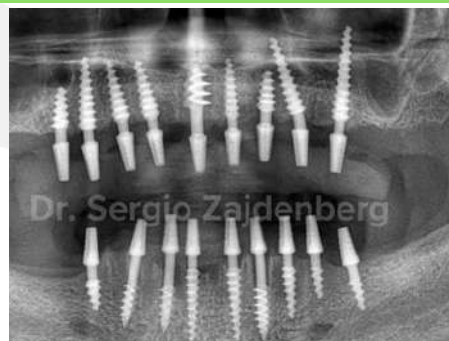- Periodontist & Oral Implantologist based in Buenos Aires, Argentina
- Over 28 years of clinical experience in dentistry and implantology
- Specialist in full-arch rehabilitation, implant-supported prosthetics, and complex edentulous cases
- Advanced focus on monoblock implantology and restorative implant workflows
- Active international lecturer conducting courses, seminars, and hands-on training in implantology
- Educator in Implantología Monoblock programs and clinical case-based learning
- Extensive experience in crowns, bridges, overdentures, and complete implant restorations
- Collaborates with leading implantology platforms including ROOTT Argentina



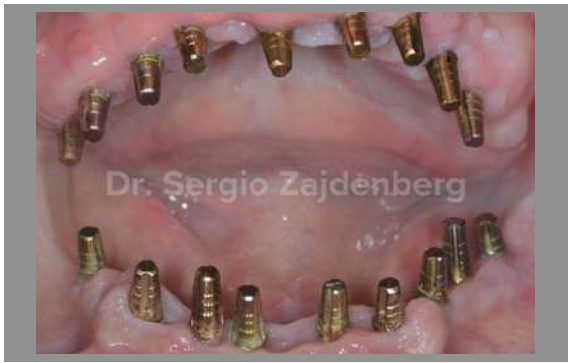Preoperative clinical Situation Edentulous upper arch & Failing lower dentition



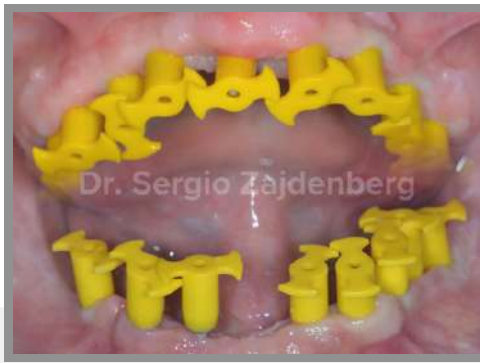ROOTT C and ROOTT B placed minimal invasive



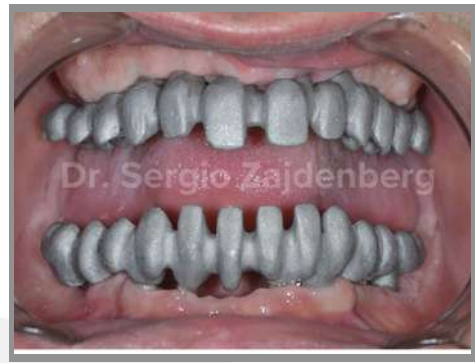Post Operative panoramic Xray implants placed at strategic location with Biomechanical perspective



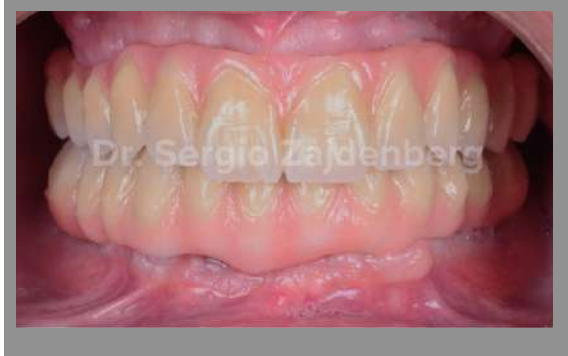Implants Healed with tissue conditioning



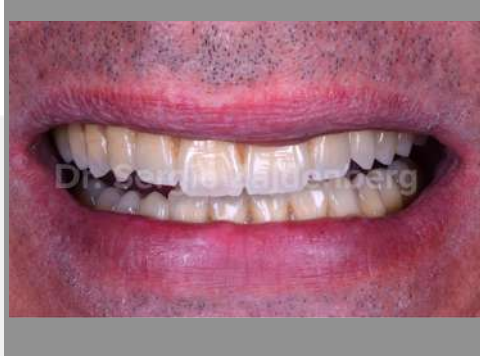Impression taking with TRA snap-on closed tray technique



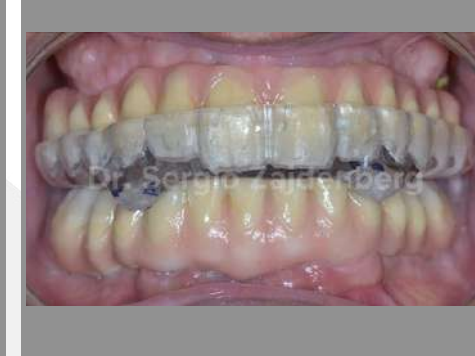Metal Try-in assesment for clearance and porcelian space



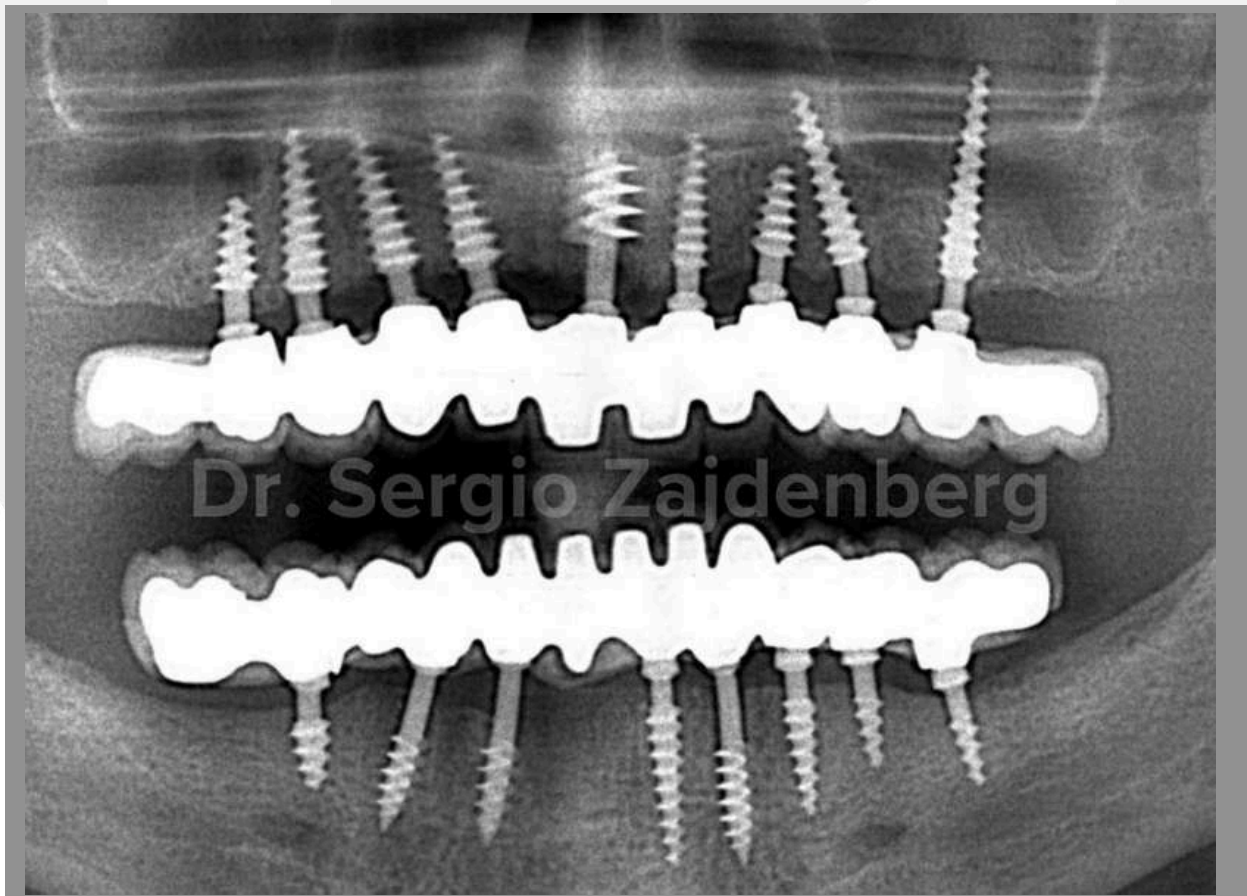
Final PFM Prosthesis in patient



Patient Bite & aesthetic assesment



Bite Splint to protect from parafunction during healing & establish new Implant occlusion



Final panoramic Xray post prosthetic delivery

**WE  IMPLANTS**